

# Wiyono Hadi

## 1-Osteitis\_in\_chronic\_rhinosinusitis\_dr.Wiyono

 Osteitis in Chronic Rhinosinusitis: A State-of-the- Art Review

---

### Document Details

Submission ID

trn:oid:::3618:120865246

Submission Date

Nov 11, 2025, 10:55 AM GMT+7

Download Date

Nov 11, 2025, 11:13 AM GMT+7

File Name

1-Osteitis\_in\_chronic\_rhinosinusitis\_dr.Wiyono.pdf

File Size

1.6 MB

10 Pages

6,894 Words

37,253 Characters





# 9% Overall Similarity

The combined total of all matches, including overlapping sources, for each database.




## Exclusions

- 2 Excluded Sources
- 139 Excluded Matches

## Match Groups

-  **40 Not Cited or Quoted** 6%  
Matches with neither in-text citation nor quotation marks
-  **18 Missing Quotations** 3%  
Matches that are still very similar to source material
-  **0 Missing Citation** 0%  
Matches that have quotation marks, but no in-text citation
-  **0 Cited and Quoted** 0%  
Matches with in-text citation present, but no quotation marks

## Top Sources

- 6%  Internet sources
- 7%  Publications
- 4%  Submitted works (Student Papers)

## Integrity Flags

0 Integrity Flags for Review

Our system's algorithms look deeply at a document for any inconsistencies that would set it apart from a normal submission. If we notice something strange, we flag it for you to review.

A Flag is not necessarily an indicator of a problem. However, we'd recommend you focus your attention there for further review.

## Match Groups

- 40 Not Cited or Quoted** 6%  
Matches with neither in-text citation nor quotation marks
- 18 Missing Quotations** 3%  
Matches that are still very similar to source material
- 0 Missing Citation** 0%  
Matches that have quotation marks, but no in-text citation
- 0 Cited and Quoted** 0%  
Matches with in-text citation present, but no quotation marks

## Top Sources

- 6% Internet sources
- 7% Publications
- 4% Submitted works (Student Papers)

## Top Sources

The sources with the highest number of matches within the submission. Overlapping sources will not be displayed.

1	Internet	cyberleninka.org	<1%
2	Internet	pmc.ncbi.nlm.nih.gov	<1%
3	Internet	ueaeprints.uea.ac.uk	<1%
4	Internet	www.mdpi.com	<1%
5	Publication	Mingjie Wang, Ting Ye, Na Liang, Zhenxiao Huang, Shunjiu Cui, Yunchuan Li, Qian...	<1%
6	Student papers	Universitas Diponegoro on 2023-05-23	<1%
7	Internet	insubriaspaces.cineca.it	<1%
8	Publication	Zhaoxue Zhai, Liting Shao, Zhaoyang Lu, Yujuan Yang et al. "Characteristics of mu...	<1%
9	Student papers	Chulalongkorn University on 2023-07-27	<1%
10	Internet	kuscholarworks.ku.edu	<1%

11	Internet	www.sirirajmedj.com	<1%
12	Publication	Glynnis De Greve, Peter W. Hellings, Wytske J. Fokkens, Benoit Pugin, Brecht Steel...	<1%
13	Publication	Andrianifahanana, M.. "Regulation of mucin expression: Mechanistic aspects and ...	<1%
14	Student papers	Universiti Sains Malaysia on 2019-10-09	<1%
15	Internet	www.dovepress.com	<1%
16	Internet	d.docksci.com	<1%
17	Student papers	Royal College of Surgeons in Ireland on 2025-09-16	<1%
18	Internet	arxiv.org	<1%
19	Publication	Bing Zhong, Jun Jie Seah, Feng Liu, Luo Ba, Jintao Du, De Yun Wang. "The role of h...	<1%
20	Student papers	Centre for Nutrition Education & Lifestyle Management (CNELM) on 2025-11-05	<1%
21	Publication	Naveen D. Bhandarkar. "The impact of osteitis on disease severity measures and ...	<1%
22	Internet	english.cjebm.com	<1%
23	Internet	repositorio.unifesp.br	<1%
24	Internet	www.nature.com	<1%

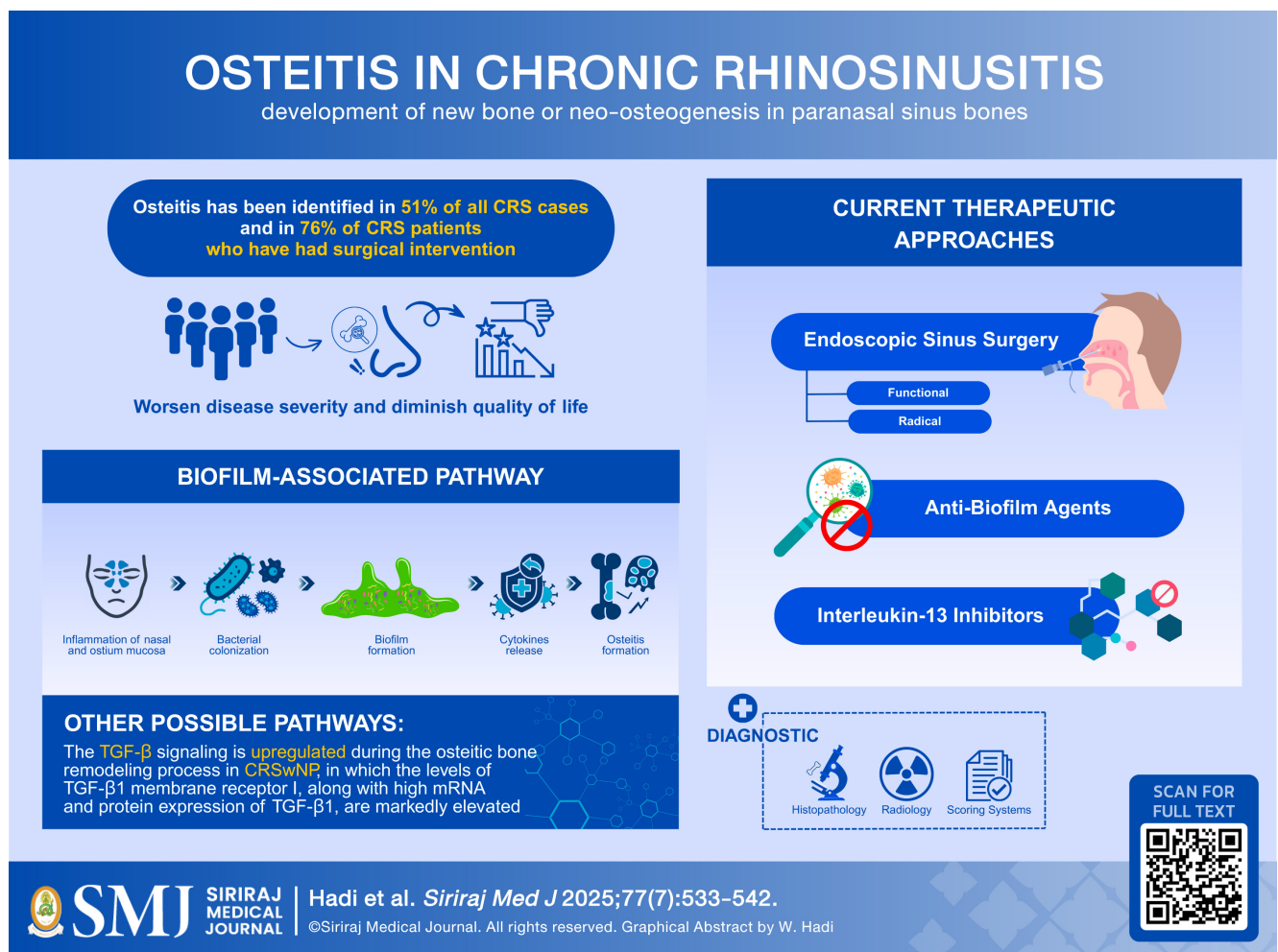
25	Student papers	University of Arizona on 2016-11-23	<1%
26	Internet	link.springer.com	<1%
27	Publication	Georgalas, Christos, and Wytske Fokkens. "Imaging as a Diagnostic Tool and Surg...	<1%
28	Publication	Kornkiat Snidvongs, Peter Earls, Dustin Dalgorf, Raymond Sacks, Eleanor Pratt, Ri...	<1%
29	Publication	Roza Khalmuratova, Hyun-Woo Shin, Dae Woo Kim, Jong-Wan Park. "Interleukin (I...	<1%
30	Publication	Sacks, Peta-Lee, Kornkiat Snidvongs, Darren Rom, Peter Earls, Raymond Sacks, an...	<1%
31	Student papers	Universita' di Siena on 2024-02-13	<1%
32	Internet	hdl.handle.net	<1%
33	Internet	sciencebiology.org	<1%
34	Internet	www.cancerindex.org	<1%
35	Student papers	Associatie K.U.Leuven on 2020-05-20	<1%
36	Internet	digital.library.adelaide.edu.au	<1%
37	Internet	discovery.researcher.life	<1%
38	Internet	www.ahns.info	<1%

39	Publication	Gayatri B. Patel, Robert C. Kern, Jonathan A. Bernstein, Park Hae-Sim, Anju T. Pete...	<1%
40	Publication	Jin Youp Kim, Suha Lim, Hee-Suk Lim, Yi-Sook Kim et al. "Bone morphogenetic pro...	<1%
41	Publication	Practical Medical and Surgical Management of Chronic Rhinosinusitis, 2015.	<1%
42	Publication	Hao Lv, Peiqiang Liu, Yunfei Wang, Jingyu Huang, Yulie Xie, Mengting Guan, Jianc...	<1%
43	Publication	Kijeong Lee, Junhu Tai, Sang Hag Lee, Tae Hoon Kim. "Advances in the Knowledge...	<1%
44	Publication	S Aparna, Shibu George. "The Impact of Osteitis on Quality of Life in Patients with...	<1%
45	Publication	So Yeon Yoon, Seung-No Hong, Yan Lee, Dae Woo Kim. "Clinical and immunologic ...	<1%

# Osteitis in Chronic Rhinosinusitis: A State-of-the-Art Review

Wiyono Hadi, M.D., Ph.D.<sup>1,\*</sup>, Widia Isa Aprillia Sujana, M.D.<sup>1</sup>, Gilang Hadi Fiandani, M.D.<sup>2</sup>

<sup>1</sup>Department of Otorhinolaryngology – Head and Neck Surgery, Faculty of Medicine, Universitas Katolik Widya Mandala Surabaya, Surabaya, Indonesia, <sup>2</sup>Department of Otorhinolaryngology – Head and Neck Surgery, Faculty of Medicine, Universitas Airlangga, Dr. Soetomo General Academic Hospital, Surabaya, Indonesia.



\*Corresponding author: Wiyono Hadi

E-mail: wiyono@ukwms.ac.id

Received 3 March 2025 Revised 17 April 2025 Accepted 20 April 2025

ORCID ID: <http://orcid.org/0009-0007-4866-1683>

<https://doi.org/10.33192/smj.v77i7.274010>



All material is licensed under terms of the Creative Commons Attribution 4.0 International (CC-BY-NC-ND 4.0) license unless otherwise stated.

## ABSTRACT

Chronic rhinosinusitis (CRS) is characterized by inflammation of the nasal mucosa and paranasal sinuses. Mucosal inflammation can induce bone remodeling leading to osteitis. Paranasal sinus osteitis is a relatively new clinical finding, describing changes in the bone due to inflammation that will damage the lamellar bone structure and new bone formation. As many as 36-53% of CRS patients have osteitis, which makes CRS difficult to cure despite adequate management and is related to a substantial number of revision surgeries. Understanding all the evidence regarding osteitis in CRS is critical in discovering effective treatments for this incurable disease. Hence, we summarize the essential yet well-established features of osteitis in CRS, including the updated definition, the role of biofilm formation along with cytokines and runt-related transcription factor 2 axis as its possible underlying pathogenesis, the transforming growth factor beta signaling pathway of the disease, histopathological bone changes, radiographic staging and scoring systems, disease impacts on the CRS severity and quality of life, as well as the most up-to-date treatment strategies for osteitis in CRS. These include functional or radical endoscopic sinus surgery, interleukin-13 inhibitors, anti-biofilm agents, high-dose intranasal corticosteroids, and other potential therapies.

**Keywords:** Bone remodeling; chronic rhinosinusitis; hyperostosis; neo-osteogenesis; osteitis (Siriraj Med J 2025; 77: 533-542)

## INTRODUCTION

Chronic rhinosinusitis (CRS) is a long-term, multifactorial inflammatory disease of the nose and paranasal sinuses, characterized by the presence of at least two such symptoms as: olfactory dysfunction, facial pain, one of which must be anterior/posterior nasal discharge or nasal blockage that lasts for 12 weeks or greater.<sup>1</sup> CRS can be classified into primary and secondary CRS. The primary CRS is divided into two subtypes based on the type of inflammation, consisting of eosinophilic or type 2 and neutrophilic or non-type 2 CRS.<sup>1-3</sup> CRS is also phenotypically divided into CRS with nasal polyps (CRSwNP) and CRS without nasal polyps (CRSsNP).<sup>1-3</sup> CRS prevalence ranged from 3% to 8.7% of the global population.<sup>4,5</sup>

Experiences of persistent or even deteriorating symptoms of CRS after having adequate management have become a global concern. Moreover, there are cases where the symptoms fail to improve after sinus surgery.<sup>6,7</sup> These conditions are called recalcitrant or refractory CRS (RCRS).<sup>8</sup> Osteitis, the involvement of the newly developed paranasal sinus bones from the inflammatory process in CRS, had been considered the critical cause of RCRS and the high rate of revision surgeries.<sup>9</sup> The presence of osteitis may also be associated with a high risk of increasing intraoperative bleeding due to the challenge of removing the thick bone. Osteitis is also associated with CRS severity.<sup>10</sup> Osteitis has been identified in 51% of all CRS cases and 76% of patients with CRS who have had surgical intervention.<sup>11</sup>

Osteitis in CRS, together with its biomolecular mechanism, remains poorly understood owing to the wide variety of statements in the literature. Its existence is also often

unrecognized by clinicians. In this review, we summarize the updated definition, the role of biofilm formation along with cytokines and runt-related transcription factor 2 (RUNX2) axis as its possible underlying pathogenesis, the transforming growth factor beta (TGF- $\beta$ ) signaling pathway of the disease, histopathological bone changes, radiographic staging and scoring systems, disease impacts on the CRS severity and quality of life (QoL), as well as the most up-to-date treatment strategies for osteitis in CRS.

### Definition

Osteitis is the accepted term for the bone thickening of paranasal sinuses based on computed tomography (CT) because the underlying sinuses bones, except the frontal sinuses, are void of bone marrow.<sup>12</sup> Osteitis is first described as the inflammation of bone that lacks marrow space.<sup>13</sup> An inflammatory involvement and the expansion of the Haversian canal system have been demonstrated in animal studies.<sup>14-16</sup> Since then, several human studies have contributed further to define osteitis better.

Some human histopathological studies have revealed no involvement of inflammatory cytokines in the osteitic bone.<sup>9,17,18</sup> In contrast, other newest study demonstrated the eosinophils involvement in human osteitic bone and reported the different roles of this signaling pathway between CRSwNP and CRSsNP.<sup>19</sup> Recently, there was also a reported association between IL-13 and osteitis in type 2 CRS.<sup>20</sup> These studies suggest the involvement of inflammatory agents in the underlying sinus bones and indicate that the osteitis formation varies depending on the CRS classification.



Eventually, based on recent evidence, osteitis in CRS has been temporarily defined as the development of new bone or neo-osteogenesis and bone remodeling in paranasal sinus bones. Further larger and specific studies need to be done to reach a consensus due to the controversy of whether: Osteitis is a form of isolated new bone formation resulting from the locally infected sinus mucosa rather than direct inflammation of underlying sinus bone; or the inflammation process in the underlying sinus bone serves as a storage for inflammatory cytokines, resulting from an expansion of the Haversian canal system and the infiltration of inflammatory cells into an augmented vascular network.

## Epidemiology

A study by Lee et al.<sup>9</sup> in 2006, with a sample of 121 CRS patients, showed that 36-53% of CRS patients were found to have osteitis using radiological and histopathological criteria. Mild osteitis was found in 73% of samples, moderate osteitis in 45%, and severe osteitis in 18% of samples. The incidence of osteitis was also shown to increase with increasing Lund-Mackay (LM) score. Georgalas et al.<sup>7</sup> in 2010 also stated that the prevalence of bone involvement in CRS cases was 33% in the group that had never undergone surgery, but increased to 75% in CRS patients with a history of previous surgery. Hyperostosis and heterogeneity of the sinus wall were seen in 63.7% of CRS patients and 10% in the control group, but those who met the significant criteria of the Global Osteitis Scoring Scale (GOSS), which scores more than 5, was 40% in CRS group and 0 in the control group. CRSwNP were also seen to have a greater percentage of osteitis than CRSsNP (73% vs 55%,  $p = 0.04$ ).<sup>7</sup>

## Pathogenesis and molecular mechanism

### Role of biofilm formation, cytokines, and RUNX2 Axis

The endotypes of CRS were classified based on the pattern of cytokine production from regulatory immune cells. Eosinophilic CRS, referred to as type 2 CRS, consists of several interleukins (ILs), including IL-4, IL-5, IL-9, and IL-13 cytokines regulated by Th2 cells, mast cells, group 2 innate lymphoid cells (ILC2s), and eosinophils. Non-eosinophilic or neutrophilic CRS consists of type 1 and type 3 CRS. Type 1 CRS consists of interferon-gamma (IFN- $\gamma$ ) regulated by Th1 cells, cytotoxic T cells (CD8+ T), natural killer (NK) cells, and group 1 innate lymphoid cells (ILC1s). Type 3 CRS consists of IL-17 and IL-22, regulated by Th17 cells and group 3 innate lymphoid cells (ILC3s).<sup>1-3</sup>

Various variables, including mucociliary clearance

dysfunction, dysbiosis of sinus microbiota, epithelial barrier impairment, and immune system abnormalities, may facilitate the invasion of pathogens, hence fostering infection.<sup>21-23</sup> Infection induces an inflammatory response of the sinus mucosa, leading to the narrowing or complete obstruction of the sinus entry. Obstruction of the ostium reduces oxygen tension within the sinus, causing sinusitis.<sup>24</sup> Ostium sinus obstruction also enhances the trapping and buildup of mucus secretions from goblet cells. Interestingly, certain bacteria, particularly *Pseudomonas aeruginosa*, have special preference for living in mucus.<sup>25</sup> Retention of mucus together with the bacteria will trigger inflammatory reactions, thereby enhancing the bacterial activity within the sinus. Eight mucin genes have been detected in CRS tissues, including two membrane-bound mucins called MUC1 and MUC4, and six secreted mucins called MUC2, MUC5AC, MUC5B, MUC6, MUC7, and MUC8. Research have established a positive association between IL-13 and MUC5AC expression, showing that IL-13 can directly regulate mucin hypersecretion in a type 2 CRS.<sup>26</sup>

An environment with a crowded bacterial population in the paranasal sinuses encourages a shift in bacterial states from a planktonic form (free-living bacteria) to a sessile form (attached-living bacteria), which supports the process of biofilm formation.<sup>27</sup> The primary biofilm formation process occurs in several stages, including attachment, microcolony formation, matrix production, and detachment.<sup>27,28</sup> The extracellular polymeric substance (EPS) matrix in biofilm causes bacteria to become resistant to antibiotics and protects them from the host's immune system.<sup>27-29</sup> These cause the exhibit of the biofilm life cycle, thus promoting more bacterial colonies to grow and ultimately worsening the CRS. Two major bacteria that often play a role in biofilm formation in CRS are *Staphylococcus aureus* and *P. Aeruginosa*.<sup>30-32</sup>

High levels of pro-inflammatory cytokines that accumulate due to biofilm-infected sinus promote its infiltration process into the bone around. The interaction of these cytokines in the bone affects the remodeling process.<sup>33</sup> Bone remodeling is a physiological process that equilibrates the activity of osteoclasts and osteoblasts. In chronic or persistent inflammation, such as in CRS, there exists an imbalance between osteogenesis by osteoblasts and bone resorption by osteoclasts.<sup>33</sup>

IL-13 releases, particularly in eosinophilic CRS, elevates the expression of runt-related transcription factor 2 (RUNX2), which enhances osteoblast proliferation and activation, thereby augmenting the neo-osteogenesis process.<sup>34</sup> IL-13 also inhibits the synthesis of cyclooxygenase-2 (COX-2)-dependent prostaglandins (PG), thereby

reducing osteoclast production and its function in the bone resorption process. Increased osteoblast activity and decreased osteoclast production cause bone thickening, a typical sign of osteitis in CRS.<sup>35</sup> IL-13 and IL-4 in cultured human osteoblast (hOBs) have also found to have a regulation effect in osteoblasts activity by increasing the osteoblast differentiation, collagen secretion, alkaline phosphatase (ALP) expression, and mineralization, thereby increasing neo-osteogenesis.<sup>36</sup> However, further studies analyzed the role of IL-13 and other cytokines on osteitis formation in CRS with a large population, and multi-centered research, including assessing all CRS phenotypes, need to be investigated to avoid potential biases.

Research revealed that of all the cytokines produced by each endotype in CRS, only IL-4, IL-13, and IL-17 play an essential role in osteitis in CRS through the mechanism of neo-osteogenesis.<sup>37</sup> However, research has shown that IL-17 also induces the receptor activator of nuclear factor kappa-B ligand (RANKL) in osteoblasts. This results in inflammation and bone destruction by activating osteoclasts in other chronic inflammatory diseases, such as rheumatoid arthritis. This finding resulted in a mixture of mechanisms between neo-osteogenesis and osteolysis in non-eosinophilic CRS.<sup>37,38</sup> Therefore, it also explains why the prevalence of neo-osteogenesis is higher in eosinophilic CRS than in non-eosinophilic.<sup>20</sup>

### Role of TGF- $\beta$ signaling pathway

Transforming growth factor beta (TGF- $\beta$ ) is a multifunctional cytokine with three isoforms: TGF- $\beta$ 1, TGF- $\beta$ 2, and TGF- $\beta$ 3, which interact with membrane R types I, II, and III.<sup>39</sup> The TGF- $\beta$ 1 is involved in airway

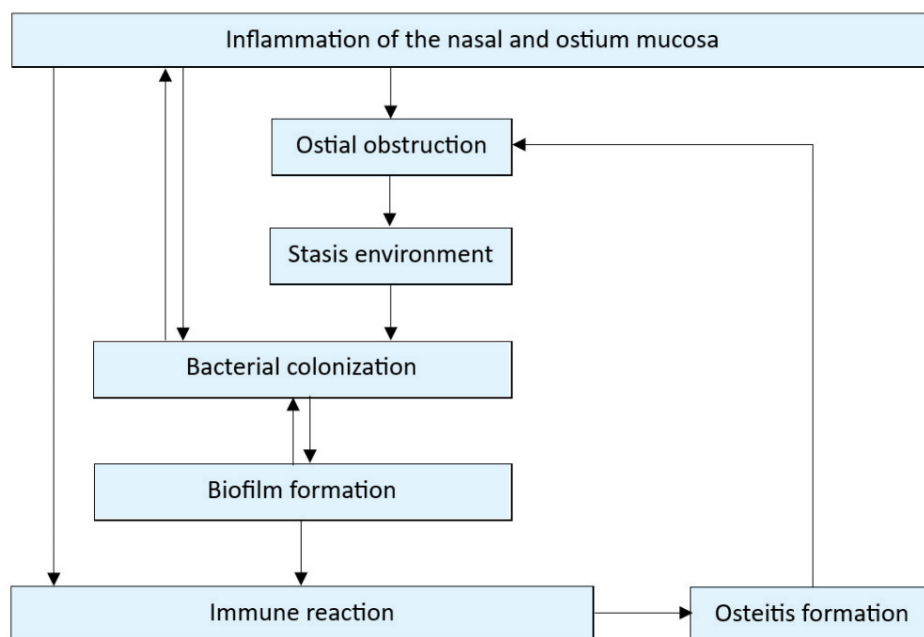
pathologies and plays a different role in mucosal and bone tissues in CRS patients.<sup>40</sup> TGF- $\beta$ 1 in mucosal tissue is elevated in CRSsNP but diminished in CRSwNP.<sup>41,42</sup> In contrast, TGF- $\beta$ 1 levels were elevated in CRSwNP bone specimens and exhibited a correlation with osteitis bone grading when compared to CRSsNP, as determined by reverse transcription polymerase chain reaction (RT-PCR) and immunohistochemistry (IHC) staining.<sup>19</sup>

Previously in 2003, Park et al.<sup>43</sup> reported that TGF- $\beta$  could significantly reduce COX-2 mRNA levels. Moreover, Takai et al.<sup>44</sup> in 2013 demonstrated that TGF- $\beta$ 1 induced downregulation of COX-2, leading to decreased synthesis of PGE2. These results indicate that the TGF- $\beta$  signaling pathway is upregulated during the osteitic bone remodeling process in CRSwNP. Wang et al.<sup>19</sup> in 2015 noted markedly elevated levels of TGF- $\beta$ 1 RI together with high messenger ribonucleic acid (mRNA) and protein expression of TGF- $\beta$ 1, in the osteitic ethmoid bone of CRSwNP patients relative to control and CRSsNP groups. TGF- $\beta$ 1 expression was observed in eosinophils and osteoblasts of the CRSwNP group, but was infrequently detected in the control and CRSsNP groups. However, this preliminary study needs further research with larger sample sizes and specific analyses. The summary of the pathogenesis of osteitis in CRS can be seen in Fig 1.

### Diagnosis

#### Histopathological bone changes

Histology is an examination that is considered to be the most accurate diagnosing method for a disease accompanied by structural changes such as osteitis. The histopathological findings of osteitis in CRS include



**Fig 1.** Summary of the pathogenesis of osteitis in chronic rhinosinusitis associated with biofilm formation and immune reaction.

18

thickening of the periosteum, increased activity of osteoblast-osteoclast characterized by the presence of osteoblast or multinucleated osteoclast, dominated woven bone formation of total bone thickness, and fibrosis.<sup>45</sup> Newly formed bone in osteitis is a form of immature woven bone with a weaving arrangement of collagen fibers, making it more flexible and weaker than the mature lamellar bone with strong structured collagen fibers.<sup>46</sup>

Radiographic staging systems

Although histological examination provides a precise way to diagnose osteitis, radiological investigations are generally performed to diagnose osteitis in CRS. The neo-osteogenesis criteria for osteitis in CRS are bone thickening of more than 3 mm with a density of more than 500 Hounsfield units (HU) in CT measures (Table 1).<sup>9,45,47-50</sup> A study by Lee et al. in 2006 reported that CT imaging showed neo-osteogenesis in 36% of

patients while 53% showed histopathological evidence of osteitis of bone specimens.<sup>9</sup> An example of a CT image of osteitis in a patient with CRS can be seen in Fig 2.

Single-photon emission computed tomography (SPECT) is a nuclear medicine imaging technology that employs the intravenous administration of radioactive isotopes prior to imaging.<sup>51</sup> SPECT is a more sensitive method for detecting acute or mild bone remodeling; in contrast, CT observed only a significant thickening of bone density that is usually considered chronic or severe.<sup>51</sup> SPECT may detect milder instances of osteitis, hence averting revision procedures resulting from the ongoing disease progression.<sup>49</sup> Nonetheless, compared to CT, SPECT is probably impractical for a regular application owing to its elevated cost, extended procedural duration, and increased invasiveness resulting from exposure to radioactive isotopes or contrast agents.<sup>51,53</sup> The SPECT imaging had a specificity of 66.7% and positive predictive value of 96.9% in detecting osteitis in CRS, compared to histopathologic bone changes.<sup>53</sup>

TABLE 1. Osteitis severity based on the bone thickness of computed tomography measurement.

Osteitis Severity	Bone Thickness (mm)
Not Significant	<3
Mild	3
Moderate	4-5
Severe	>5

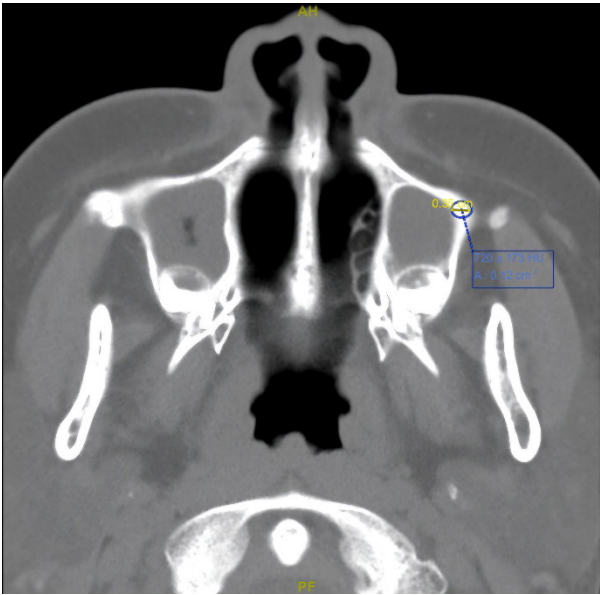


Fig 2. A computed-tomography image of osteitis in a chronic rhinosinusitis patient showed 3.5 mm bone thickening with a density of 720±173 Hounsfield units around the maxillary sinus.

Scoring systems

Currently, there are widely accepted and agreed-upon osteitis assessment criteria. Some of them are Kennedy Osteitis Score (KOS), GOSS, and Modified GOSS. Original KOS classified the osteitis as mild, moderate, or severe depending on the extent of bony thickness on all sinuses except the frontal sinuses. GOSS assesses ten sinuses with an addition of the percentage of sinus wall involvement, while Modified GOSS only assesses four sinuses.<sup>54</sup>

The severity of osteitis can be graded using the GOSS, the current most validated radiological grading system based on CT imaging.<sup>7,11</sup> GOSS is the best scoring system in detecting extensive bone changes in the paranasal sinus walls, because in addition to severity, the percentage of bone involvement is also measured. When using GOSS, clinicians must evaluate for loss of bone definition, hyperostosis, new bone formation, or signs of heterogeneity in each paranasal sinus wall.<sup>54</sup> The maximum thickness area of the osteitic bone of each sinus is measured and then assigned as grading from 0 to 5, as seen in Table 2. The possible range of GOSS is between 0 and 50, based on the total or global osteitis score of all ten sinuses.<sup>7</sup> Higher grades indicate greater osteitis severity.

Disease impacts

CRS severity

Osteitis grade has proven to have a proportional correlation to the increased CRS severity.<sup>55</sup> The LM scoring system is a diagnostic instrument utilized to

6

26

44

**TABLE 2.** Global osteitis scoring scale.

Osteitis Grade	Involvement of Sinus Wall (%)	Bone Thickness (mm)
1	<50	<3
2	<50	3-5
3	<50	>5
3	>50	<3
4	>50	3-5
5	>50	>5

Total score interpretation: <5 = not significant; 5-20 = mild; 20-35 = moderate; >35 = severe

evaluate the severity of CRS.<sup>56</sup> Higher scores indicate greater CRS severity. Studies have demonstrated the association between the LM scoring system and the GOSS score.<sup>9,20,55,57,58</sup> CRS patients with osteitis have been reported to have worse baseline disease severity compared to CRS patients without osteitis, as measured by several diagnostic examinations, including endoscopy, CT imaging, or olfactory function assessment.<sup>55</sup>

### Quality of life

An earlier study reported that osteitis significantly affected the QoL along with its severity.<sup>59</sup> The most widely accepted subjective assessment for assessing QoL in CRS patients is the Sinonasal Outcome Test-22 (SNOT-22), a derivative of the SNOT-16 and SNOT-20.<sup>60</sup> Unlike the previous versions, the symptoms of nasal obstruction and loss of smell and/or taste have been added in SNOT-22, with possible total scores between 0 and 110.<sup>61</sup> However, a previous study reported no association between osteitis and the QoL.<sup>55</sup> Potential confounding factors, such as CRS phenotype or comorbidities, should be of greater concern to researchers to obtain more accurate conclusions regarding the relationship between osteitis and QoL.

## Treatment strategies

### Surgical techniques

Surgical treatment under endoscopic sinus surgery (ESS) has become the standard treatment for treating osteitis in CRS, with experts recommending removing osteitic bone wherever feasible.<sup>62</sup> The two best-known surgical techniques for osteitis are functional ESS (FESS) and radical ESS (RESS). FESS focused on removing any causes of sinus obstruction, including the osteitic bone, thus improving the ventilation and function of the sinus.<sup>63</sup> RESS focused on resecting all walls between the

nasal fossa and paranasal sinuses, resulting in a singular extensive cavity.<sup>64,65</sup> Although RESS is not widely used in clinical practice due to the possible physiological function of sinus impairment, a study conducted by Wang et al. in 2021 has reported the effectiveness of RESS compared to FESS, in which RESS provided a lower LM score than in the FESS group one year after surgery.<sup>65</sup> In contrast, a recent study conducted by Aldajani et al. in 2024 has reported no significant differences between RESS and Primary Endoscopic Sinus Surgery (PESS), a comprehensive full-house FESS, in 12 months follow-up period.<sup>66</sup> These results indicated that a longer follow-up duration and a better study design needs to be conducted to determine the effectiveness of RESS and FESS for osteitis management in CRS.

### Potential biologic agents

IL-13 is a natural pro-inflammatory cytokine highly secreted in eosinophilic CRS, including CRSwNP or CRSsNP, but especially in CRSwNP.<sup>67</sup> IL-13 in CRS binds to the IL-13 alpha 2 receptor (IL-13Ra2) in sinonasal epithelial cells.<sup>68</sup> Research has shown that IL-13Ra2 receptors in CRS patients with osteitis are higher than in healthy patients.<sup>37</sup> It implied that IL-13 plays a significant role in osteitis formation in CRS. In addition, it also can be hypothesized that eosinophilic CRS patients with osteitis are more likely to experience RCRS caused by the high level of IL-13 and the large number of IL-13Ra2 receptors, which support the severity of osteitis in CRS. Therefore, inhibition of IL-13 is one of the effective strategies that can be explored and developed to prevent the occurrence of osteitis in eosinophilic CRS, which can ultimately reduce the incidence of RCRS. Khalmuratova et al.<sup>67</sup> in 2020 proved that resveratrol suppressed the expression of IL-13, RUNX2, and osteoblasts in a mouse model of



CRS induced by 3% ovalbumin and 10 ng Staphylococcal enterotoxin B (OVA/SEB). Further studies or clinical trials examining the efficacy of IL-13 inhibitors in CRS patients with osteitis are awaited.

### Additional possible therapies

Mukerji et al.<sup>69</sup> in 2009 demonstrated a placebo-controlled trial in 77 CRS patients receiving *Lactobacillus rhamnosus* or placebo orally for four weeks. Results revealed that *L. rhamnosus* is an ineffective adjuvant therapy for CRS, as there were no significant differences in SNOT-20 scores between the *L. rhamnosus* group and the placebo group. Other research, such as the application of baby shampoo irrigation, has shown considerable enhancement in CRS patients following FESS. However, it also resulted in several intolerable side effects, including nasal burning and headaches, making baby shampoo a less feasible treatment option for CRS.<sup>70</sup>

Alandejani et al.<sup>71</sup> in 2009 reported the significant bactericidal effect of Manuka honey against planktonic and biofilm forms of *S. aureus* and *P. aeruginosa*. Methylglyoxal (MGO) is the main active ingredient found in Manuka honey. MGO has been reported to be able to reduce biofilm biomass at 1.8 mg/mL and 3.6 mg/mL in a sheep model for CRS.<sup>72</sup> However, animal studies demonstrated that MGO given alone had more toxic effects, such as metaplasia of respiratory epithelium and severe sinus inflammation, compared with MGO given with Manuka honey. This result suggests that MGO does not have its effects alone and requires the other components in Manuka honey to provide significant advantages.<sup>71,72</sup>

Jervis-Bardy et al.<sup>73</sup> in 2012 performed a randomized controlled clinical trial involving 25 RCRS patients following FESS. Patients were randomized to receive twice-daily nasal rinses for one-month with either 0.05% Mupirocin or oral Augmentin. After one month, negative culture results were observed in 89% of the mupirocin group, whereas the placebo group exhibited 0% findings. However, re-evaluation in the mupirocin cohort at two to six months revealed positive culture results for *S. aureus* in 83.3% of individuals.

Kurasirikul et al.<sup>74</sup> in 2014 performed a retrospective cohort study of 38 children with CRS given gentamicin nasal irrigation. The results showed significant improvements in several parameters, such as nasal congestion, rhinorrhea, itching, post-nasal drip, purulent nasal discharge, halitosis, chronic cough, sneezing, and anosmia. However, further longer follow-up and RCT studies should be performed to better assess the efficacy and toxicity.

Several researchers have reported the concept of biofilm-induced CRS.<sup>75-77</sup> Previous human studies

reported the correlation between the volume of bacterial biofilm and the severity of osteitis in CRS.<sup>78</sup> Hadi et al.<sup>79</sup> in 2019 revealed antimicrobial and antibiofilm effects of the Indonesian ethanolic extract of propolis *Trigona spp.* (IEEP-TRI) against *S. aureus* isolated from CRS patients using two-dimensional confocal laser scanning microscopy (CLSM). IEEP-TRI also showed a reduction effect in autoinducer peptides (AIP), the quorum-sensing molecules secreted by *S. aureus* in the biofilm-associated CRS mechanism.

High doses of intranasal corticosteroids (INCS), including Fluticasone 400 µg/200 µL, Budesonide 750-2000 µg/200 µL, and Mometasone 200-400 µg/200 µL, had been shown to have a direct in vitro effect in reducing biofilm biomass by up to 99%.<sup>80</sup> These findings elucidate a novel mechanism of action of INCS against biofilm in CRS, thus preventing the formation of osteitis and necessitating further investigation.

## CONCLUSION

Osteitis is characterized by neo-osteogenesis of woven bone around the infected paranasal sinus and is regarded as a complex condition related to CRS severity and QoL. Osteitis in CRS is linked to biofilm formation, inflammatory cytokine presence, RUNX2 regulation, and TGF-β signaling. Diagnostic tools include both histopathological and radiographic staging and scoring systems. Therapy involves surgical interventions such as FESS or RESS. IL-13 inhibitors, anti-biofilm agents, and high-dose INCS present possible mechanisms of action against osteitis in CRS. Thus, future studies necessitate a better understanding of the inflammatory involvement in the underlying sinus bones of CRS, alongside additional investigations into its pathogenesis and molecular mechanisms in human clinical trial studies in large sample sizes, so that it may aid the discovery of novel therapeutic agents for the disease. Future long-term clinical efficacy studies with well-designed randomized controlled trials (RCTs) are also needed to assess their sustained benefits and safety.

## Data Availability Statement

The data underlying this study are available in the published article.

## ACKNOWLEDGEMENT

None.

## DECLARATION

### Grants and Funding Information

This study received no external funding.

## Conflict of Interest

The authors report no conflict of interest in this study.

## Registration Number of Clinical Trial

Not applicable.

## Author Contributions

Conceptualization and methodology: W.H., W.I.A.S., and G.H.F. ; Data acquisition and writing – review & editing: W.H. and G.H.F. ; Writing – original draft: W.H. and W.I.A.S.

## Use of Artificial Intelligence

This study does not use any artificial intelligence assistant.

## REFERENCES

- Fokkens WJ, Lund VJ, Hopkins C, Hellings PW, Kern R, Reitsma S, et al. European Position Paper on Rhinosinusitis and Nasal Polyps 2020. *Rhinology*. 2020;58(Suppl S29):1-464.
- Kato A, Peters AT, Stevens WW, Schleimer RP, Tan BK, Kern RC. Endotypes of chronic rhinosinusitis: Relationships to disease phenotypes, pathogenesis, clinical findings, and treatment approaches. *Allergy*. 2022;77(3):812-26.
- Kato A, Schleimer RP, Bleier BS. Mechanisms and pathogenesis of chronic rhinosinusitis. *J Allergy Clin Immunol*. 2022;149(5):1491-1503.
- Dietz de Loos D, Lourijzen ES, Wildeman MAM, Freling NJM, Wolvers MDJ, Reitsma S, et al. Prevalence of chronic rhinosinusitis in the general population based on sinus radiology and symptomatology. *J Allergy Clin Immunol*. 2019;143(3):1207-14.
- Min HK, Lee S, Kim S, Son Y, Park J, Kim HJ, et al. Global incidence and prevalence of chronic rhinosinusitis: A systematic review. *Clin Exp Allergy*. 2025;55(1):52-66.
- van der Veen J, Seys SF, Timmermans M, Levie P, Levie P, Jorissen M, Fokkens WJ, et al. Real-life study showing uncontrolled rhinosinusitis after sinus surgery in a tertiary referral centre. *Allergy*. 2017;72(2):282-90.
- Georgalas C, Videler W, Freling N, Fokkens W. Global Osteitis Scoring Scale and chronic rhinosinusitis: A marker of revision surgery. *Clin Otolaryngol*. 2010;35(6):455-61.
- Kong IG, Kim DW. Pathogenesis of recalcitrant chronic rhinosinusitis: The emerging role of innate immune cells. *Immune Netw*. 2018;18(2):e6.
- Lee JT, Kennedy DW, Palmer JN, Feldman M, Chiu AG. The incidence of concurrent osteitis in patients with chronic rhinosinusitis: A clinicopathological study. *Am J Rhinol*. 2006;20(3):278-82.
- Israchmadi A, Ningrum FH, Baskoro N, Mailasari A. Correlation between the severity of chronic rhinosinusitis and the degree of osteitis based on computerized tomography evaluation. *Medica Hospitalia J Clin Med*. 2024;11(2):209-13.
- Snidvongs K, McLachlan R, Chin D, Pratt E, Sacks R, Earls P, et al. Osteitic bone: A surrogate marker of eosinophilia in chronic rhinosinusitis. *Rhinology*. 2012;50(3):299-305.
- Saladin KS. *Anatomy & physiology: The unity of form and function*. New York, NY: McGraw-Hill Companies; 2007.
- Kennedy DW, Senior BA, Gannon FH, Montone KT, Hwang P, Lanza DC. Histology and histomorphometry of ethmoid bone in chronic rhinosinusitis. *Laryngoscope*. 1998;108(4 Pt 1):502-7.
- Westrin KM, Norlander T, Stiernä P, Carlsöö B, Nord CE. Experimental maxillary sinusitis induced by *Bacteroides fragilis*: A bacteriological and histological study in rabbits. *Acta Otolaryngol*. 1992;112(1):107-14.
- Perloff JR, Gannon FH, Bolger WE, Montone KT, Orlandi R, Kennedy DW. Bone involvement in sinusitis: An apparent pathway for the spread of disease. *Laryngoscope*. 2000;110(12):2095-9.
- Antunes MB, Feldman MD, Cohen NA, Chiu AG. Dose-dependent effects of topical tobramycin in an animal model of *Pseudomonas sinusitis*. *Am J Rhinol*. 2007;21(4):423-7.
- Cho SH, Min HJ, Han HX, Paik SS, Kim KR. CT analysis and histopathology of bone remodeling in patients with chronic rhinosinusitis. *Otolaryngol Head Neck Surg*. 2006;135(3):404-8.
- Snidvongs K, Earls P, Dalgorf D, Sacks R, Pratt E, Harvey RJ. Osteitis is a misnomer: A histopathology study in primary chronic rhinosinusitis. *Int Forum Allergy Rhinol*. 2014;4(5):390-6.
- Wang M, Ye T, Liang N, Huang Z, Cui S, Li Y, et al. Differing roles for TGF- $\beta$ /Smad signaling in osteitis in chronic rhinosinusitis with and without nasal polyps. *Am J Rhinol Allergy*. 2015;29(5):e152-9.
- Zhang Z, Zuo Q, Du Y, Jiang H, Ma F, Zhang Y. Correlation of eosinophils and type 2 inflammatory mediators with osteitis in chronic rhinosinusitis with nasal polyps. *J Inflamm Res*. 2024;17:4055-64.
- Jiao J, Wang C, Zhang L. Epithelial physical barrier defects in chronic rhinosinusitis. *Expert Rev Clin Immunol*. 2019;15(6):679-88.
- Cho DY, Hunter RC, Ramakrishnan VR. The microbiome and chronic rhinosinusitis. *Immunol Allergy Clin North Am*. 2020;40(2):251-63.
- He Y, Fu Y, Wu Y, Zhu T, Li H. Pathogenesis and treatment of chronic rhinosinusitis from the perspective of sinonasal epithelial dysfunction. *Front Med (Lausanne)*. 2023;10:1139240.
- Kim YJ, Cho HJ, Shin WC, Song HA, Yoon JH, Kim CH. Hypoxia-mediated mechanism of MUC5AC production in human nasal epithelia and its implication in rhinosinusitis. *PLoS One*. 2014;9(5):e98136.
- Hansson GC. Mucins and the microbiome. *Annu Rev Biochem*. 2020;89:769-93.
- Zhai Z, Shao L, Lu Z, Yang Y, Wang J, Liu Z, et al. Characteristics of mucin hypersecretion in different inflammatory patterns based on endotypes of chronic rhinosinusitis. *Clin Transl Allergy*. 2024;14(1):e12334.
- Rice DH. Biofilm in chronic rhinosinusitis: A review. *Med Res Arch*. 2020;8(2).
- Sauer K, Stoodley P, Goeres DM, Hall-Stoodley L, Burmølle M, Stewart PS, et al. The biofilm life cycle: Expanding the conceptual model of biofilm formation. *Nat Rev Microbiol*. 2022;20(10):608-20.
- Maina IW, Patel NN, Cohen NA. Understanding the role of biofilms and superantigens in chronic rhinosinusitis. *Curr Otorhinolaryngol Rep*. 2018;6(3):253-62.

30. Chegini Z, Noei M, Hemmati J, Arabestani MR, Shariati A. The destruction of mucosal barriers, epithelial remodeling, and impaired mucociliary clearance: Possible pathogenic mechanisms of *Pseudomonas aeruginosa* and *Staphylococcus aureus* in chronic rhinosinusitis. *Cell Commun Signal*. 2023;21(1):306.
31. Tantilipikorn P, Bunnag C, Srifuengfung S, Dhiraputra C, Tiensasitorn C, Jaroencharsri P, et al. A surveillance study of bacteriologic profile in rhinosinusitis. *Siriraj Med J*. 2007;59(4):177-80.
32. Bedavanija A, Tantilipikorn P, Banditsing C, Kiratisin P, Bunnag C. A comparison of the bacterial culture results of maxillary sinus mucosa and pus collections for chronic maxillary rhinosinusitis. *Siriraj Med J*. 2019;71(2):95-101.
33. Xu J, Yu L, Liu F, Wan L, Deng Z. The effect of cytokines on osteoblasts and osteoclasts in bone remodeling in osteoporosis: A review. *Front Immunol*. 2023;14:1222129.
34. Khalmuratova R, Park JW, Shin HW. Immune cell responses and mucosal barrier disruptions in chronic rhinosinusitis. *Immune Netw*. 2017;17(1):60-67.
35. Onoe Y, Miyaura C, Kaminakayashiki T, Nagai Y, Noguchi K, Chen QR, et al. IL-13 and IL-4 inhibit bone resorption by suppressing cyclooxygenase-2-dependent prostaglandin synthesis in osteoblasts. *J Immunol*. 1996;156(2):758-64.
36. Silfverswärd CJ, Penno H, Frost A, Nilsson O, Ljunggren O. Expression of markers of activity in cultured human osteoblasts: effects of interleukin-4 and interleukin-13. *Scand J Clin Lab Invest*. 2010;70(5):338-42.
37. Khalmuratova R, Shin HW, Kim DW, Park JW. Interleukin (IL)-13 and IL-17A contribute to neoosteogenesis in chronic rhinosinusitis by inducing RUNX2. *EBioMedicine*. 2019;46:330-41.
38. Beringer A, Miossec P. Systemic effects of IL-17 in inflammatory arthritis. *Nat Rev Rheumatol*. 2019;15(8):491-501.
39. Vander Ark A, Cao J, Li X. TGF- $\beta$  receptors: In and beyond TGF- $\beta$  signaling. *Cell Signal*. 2018;52:112-20.
40. Salib RJ, Howarth PH. Transforming growth factor-beta in allergic inflammatory disease of the upper airways: Friend or foe? *Clin Exp Allergy*. 2009;39(8):1128-35.
41. Van Zele T, Claeys S, Gevaert P, Van Maele G, Holtappels G, Van Cauwenberge P, et al. Differentiation of chronic sinus diseases by measurement of inflammatory mediators. *Allergy*. 2006;61(11):1280-9.
42. Van Bruaene N, Derycke L, Perez-Novo CA, Gevaert P, Holtappels G, De Ruyck N, et al. TGF-beta signaling and collagen deposition in chronic rhinosinusitis. *J Allergy Clin Immunol*. 2009;124(2):253-9, 259.e1-2.
43. Park YG, Kang SK, Kim WJ, Lee YC, Kim CH. Effects of TGF-beta, TNF-alpha, IL-beta and IL-6 alone or in combination, and tyrosine kinase inhibitor on cyclooxygenase expression, prostaglandin E2 production and bone resorption in mouse calvarial bone cells. *Int J Biochem Cell Biol*. 2004;36(11):2270-80.
44. Takai E, Tsukimoto M, Kojima S. TGF- $\beta$ 1 downregulates COX-2 expression leading to decrease of PGE2 production in human lung cancer A549 cells, which is involved in fibrotic response to TGF- $\beta$ 1. *PLoS One*. 2013;8(10):e76346.
45. Snidvongs K, Sacks R, Harvey RJ. Osteitis in Chronic Rhinosinusitis. *Curr Allergy Asthma Rep*. 2019;19(5):24.
46. Shapiro F, Wu JY. Woven bone overview: structural classification based on its integral role in developmental, repair and pathological bone formation throughout vertebrate groups. *Eur Cell Mater*. 2019;38:137-67.
47. Pokharel M, Khadilkar MN, Sreedharan S, Pai R, Shenoy V, Bhojwani K, et al. Bone changes in chronic rhinosinusitis: Pathological or physiological? *Indian J Otolaryngol Head Neck Surg*. 2022;74(2):178-84.
48. Cho SH, Shin KS, Lee YS, Jeong JH, Lee SH, Tae K, et al. Impact of chronic rhinosinusitis and endoscopic sinus surgery on bone remodeling of the paranasal sinuses. *Am J Rhinol*. 2008;22(5):537-41.
49. Dong Y, Zhou B, Wang X, Huang Z, Wang M, Li Y, et al. Computed tomography and histopathological evaluation of osteitis in rabbit models with rhinosinusitis. *Acta Otolaryngol*. 2017;137(5):534-40.
50. Che Z, Zhang Q, Zhao P, Lv H, Ding H, Li J, et al. Computed tomography evaluation of unilateral chronic maxillary sinusitis with osteitis. *Ear Nose Throat J*. 2023;102(5):NP237-NP244.
51. Crişan G, Moldovean-Cioroianu NS, Timaru DG, Andrieş G, Căinap C, Chiş V. Radiopharmaceuticals for PET and SPECT imaging: A literature review over the last decade. *Int J Mol Sci*. 2022;23(9):5023.
52. Jang YJ, Koo TW, Chung SY, Park SG. Bone involvement in chronic rhinosinusitis assessed by 99mTc-MDP bone SPECT. *Clin Otolaryngol Allied Sci*. 2002;27(3):156-61.
53. Catalano PJ, Dolan R, Romanow J, Payne SC, Silverman M. Correlation of bone SPECT scintigraphy with histopathology of the ethmoid bulla: Preliminary investigation. *Ann Otol Rhinol Laryngol*. 2007;116(9):647-52.
54. Li YX, Lin F, Cheng L, Huang Q, Huang ZX, Zhang XQ, Zhou B. Clinical application of modified global osteitis score in chronic rhinosinusitis. *Lin Chuang Er Bi Yan Hou Tou Jing Wai Ke Za Zhi*. 2017;31(21):1666-70.
55. Bhandarkar ND, Mace JC, Smith TL. The impact of osteitis on disease severity measures and quality of life outcomes in chronic rhinosinusitis. *Int Forum Allergy Rhinol*. 2011;1(5):372-8.
56. Brooks SG, Trope M, Blasetti M, Doghramji L, Parasher A, Glicksman JT, et al. Preoperative Lund-Mackay computed tomography score is associated with preoperative symptom severity and predicts quality-of-life outcome trajectories after sinus surgery. *Int Forum Allergy Rhinol*. 2018;8(6):668-75.
57. Cheng L, Huang ZX, Zhou B, Huang Q, Wang CS, Cui SJ, et al. Clinical implication of global osteitis score system and its role in evaluation of osteitis of chronic rhinosinusitis. *Zhonghua Er Bi Yan Hou Tou Jing Wai Ke Za Zhi*. 2013;48(2):119-22.
58. Huang Z, Hajji A, Li G, Nayak JV, Zhou B, Hwang PH. Clinical predictors of neo-osteogenesis in patients with chronic rhinosinusitis. *Int Forum Allergy Rhinol*. 2015;5(4):303-9.
59. Aparna S, George S. The impact of osteitis on quality of life in patients with chronic rhinosinusitis. *Indian J Otolaryngol Head Neck Surg*. 2023;75(Suppl 1):1056-61.
60. Gallo S, Russo F, Mozzanica F, Preti A, Bandi F, Costantino C, et al. Prognostic value of the Sinonasal Outcome Test 22 (SNOT-22) in chronic rhinosinusitis. *Acta Otorhinolaryngol Ital*. 2020;40(2):113-21.
61. Ting F, Hopkins C. Outcome measures in chronic rhinosinusitis. *Curr Otorhinolaryngol Rep*. 2018;6(3):271-5.
62. Yim MT, Smith KA, Alt JA, Orlandi RR. The value of endoscopic sinus surgery in chronic rhinosinusitis. *Laryngoscope Invest Otolaryngol*. 2021;6(1):58-63.

63. Bassiouni A, Naidoo Y, Wormald PJ. When FESS fails: The inflammatory load hypothesis in refractory chronic rhinosinusitis. *Laryngoscope*. 2012;122(2):460-6.
64. Wreesmann VB, Fokkens WJ, Knecht PP. Refractory chronic sinusitis: Evaluation of symptom improvement after Denker's procedure. *Otolaryngol Head Neck Surg*. 2001;125(5):495-500.
65. Wang M, Zhou B, Li Y, Cui S, Huang Q. Radical versus functional endoscopic sinus surgery for osteitis in chronic rhinosinusitis. *ORL J Otorhinolaryngol Relat Spec*. 2021;83(4):234-41.
66. Aldajani A, Alroqi A, Alrashidi A, Alsaif A, Almeshari S, Aldwaghri M, et al. Outcomes of endoscopic sinus surgery for chronic rhinosinusitis with nasal polyposis and risk factors of recurrence in a tertiary care teaching hospital. *Ther Adv Allergy Rhinol*. 2024;15:27534030241274764.
67. Khalmuratova R, Lee M, Park JW, Shin HW. Evaluation of neo-osteogenesis in eosinophilic chronic rhinosinusitis using a nasal polyp murine model. *Allergy Asthma Immunol Res*. 2020;12(2):306-21.
68. Hershey GK. IL-13 receptors and signaling pathways: An evolving web. *J Allergy Clin Immunol*. 2003;111(4):677-90; quiz 691.
69. Mukerji SS, Pynnonen MA, Kim HM, Singer A, Tabor M, Terrell JE. Probiotics as adjunctive treatment for chronic rhinosinusitis: A randomized controlled trial. *Otolaryngol Head Neck Surg*. 2009;140(2):202-8.
70. Chiu AG, Palmer JN, Woodworth BA, Doghramji L, Cohen MB, Prince A, et al. Baby shampoo nasal irrigations for the symptomatic post-functional endoscopic sinus surgery patient. *Am J Rhinol*. 2008;22(1):34-7.
71. Alandjani T, Marsan J, Ferris W, Slinger R, Chan F. Effectiveness of honey on *Staphylococcus aureus* and *Pseudomonas aeruginosa* biofilms. *Otolaryngol Head Neck Surg*. 2009;141(1):114-8.
72. Paramasivan S, Drilling AJ, Jardeleza C, Jarvis-Bardy J, Vreugde S, Wormald PJ. Methylglyoxal-augmented manuka honey as a topical anti-*Staphylococcus aureus* biofilm agent: Safety and efficacy in an in vivo model. *Int Forum Allergy Rhinol*. 2014;4(3):187-95.
73. Jarvis-Bardy J, Boase S, Psaltis A, Foreman A, Wormald PJ. A randomized trial of mupirocin sinonasal rinses versus saline in surgically recalcitrant staphylococcal chronic rhinosinusitis. *Laryngoscope*. 2012;122(10):2148-53.
74. Kurasirikul S, Jirapongsananurak O, Vichayanond P, Visitsunthorn N. Gentamicin nasal irrigation in children with chronic rhinosinusitis: A retrospective cohort of 38 patients. *Siriraj Med J*. 2014;66(2):28-32.
75. Al-Mutairi D, Kilty SJ. Bacterial biofilms and the pathophysiology of chronic rhinosinusitis. *Curr Opin Allergy Clin Immunol*. 2011;11(1):18-23.
76. Foreman A, Jarvis-Bardy J, Wormald PJ. Do biofilms contribute to the initiation and recalcitrance of chronic rhinosinusitis? *Laryngoscope*. 2011;121(5):1085-91.
77. Foreman A, Boase S, Psaltis A, Wormald PJ. Role of bacterial and fungal biofilms in chronic rhinosinusitis. *Curr Allergy Asthma Rep*. 2012;12(2):127-35.
78. Dong D, Yulin Z, Xiao W, Hongyan Z, Jia L, Yan X, et al. Correlation between bacterial biofilms and osteitis in patients with chronic rhinosinusitis. *Laryngoscope*. 2014;124(5):1071-7.
79. Hadi W, Handoko E, Noorhamdani, Prawiro SR. Effect of ethanolic extract propolis *Trigona* spp. Malang Indonesia on isolate *Staphylococcus aureus* biofilm architecture from chronic rhinosinusitis: A confocal laser scanning microscopic study. *Int J Pharm Sci Res*. 2019;10(6):2711-7.
80. Goggin R, Jardeleza C, Wormald PJ, Vreugde S. Corticosteroids directly reduce *Staphylococcus aureus* biofilm growth: An in vitro study. *Laryngoscope*. 2014;124(3):602-7.