

**RESEARCH ARTICLE**

## **Burn Healing Activity of Siam Weed (*Chromolaena odorata*) leaf Ethanol Extract in Second Degree Burn Wound Induced in Rats**

**Sumi Wijaya<sup>1\*</sup>, Henry Kurnia Setiawan<sup>1</sup>, Iwan Sahrial Hamid<sup>2</sup>, Cheterina Tresdiany Kolnel<sup>1</sup>**

<sup>1</sup>Faculty of Pharmacy Widya Mandala Surabaya Catholic University Indonesia,  
Jalan Kalisari Selatan 1 Surabaya 60112 East Java Indonesia.

<sup>2</sup>Faculty of Veterinary, Airlangga University, Jalan Mulyosari Surabaya 60115 East Java Indonesia.

\*Corresponding Author E-mail: [sumi@ukwms.ac.id](mailto:sumi@ukwms.ac.id)

### **ABSTRACT:**

Burns are damage to the skin caused by a source of high temperature that can affected skin cells to die. Siam weed (*Chromolaena odorata* L.), one of the tropical plants belonging to Asteraceae family traditionally can be used to accelerate burn wound healing. The aim of this study was to determine the effect of ethanol extract of Siam weed leaves (*Chromolaena odorata* L.) on burn healing activity using wound diameter and neutrophil count as parameter values. Twenty fours male white rats (*Rattus norvegicus*) were divided into 4 treatment groups, namely negative control (C-, burn wound induced, given paracetamol), positive control (C+, burn wound induced, Bioplacenton was applied to burn wound), 2 treatment group (burn wound induced, P1: Siam weed ethanol extract 5% was applied to burn wound; and P2: Siam weed ethanol extract 10% was applied to burn wound). Second degree burn wound induced in animal back's using a hot rod. The results of the experiment showed that P2 have burn wound healing properties that reduce burn wound diameters and decrease the number of neutrophils. The ethanol extract of Siam weed also possess anti-inflammatory activity and have antioxidant properties that support the ability of burn wound healing.

**KEYWORDS:** Siam Weeds, Wound diameters, Number of neutrophils, 5-Lipoxygenase, Anti-inflammatory, Antioxidant.

### **INTRODUCTION:**

Burns are tissue damage and loss caused by very high temperature sources such as fire, hot water, chemicals, electricity, and radiation<sup>1,2</sup>. Burns can cause damage and increase the permeability of capillaries, damage to skin tissue in the epidermis, dermis, and subcutaneous tissue. In severe conditions it can cause serious disorders in the lungs, kidneys and liver<sup>3</sup>. Treatment of burn wound needs to be taking care as soon as possible to reduce the possibility severe complications, such as hypovolemic shock and sepsis<sup>4</sup>. Second-degree burns, well known as deep partial-thickness burns happens when lesions penetrate into the dermis<sup>5</sup>. This type of burn wound is commonly happens in house hold.

Handling in burn healing aims to prevent infection and provide an opportunity for the remnants of epithelial cells to proliferate and close the wound surface<sup>6</sup>. Siam weed (*Chromolaena odorata* L.) belongs to the Asteraceae family and is a perennial herb that is easy to grow and found throughout tropical and subtropical region<sup>7</sup>, including in Indonesia. Siam weed leaves have been used for generations as traditional medicine for wound healing, such as soft tissue wounds, burns and skin infections<sup>8-11</sup>. Siam weed contains several main compounds, including: flavonoids<sup>12-14</sup> which have antibacterial and anti-inflammatory properties, steroids<sup>12</sup> can prevent stiffness and reduce pain, and also saponins<sup>15,16</sup> as antiseptics which kill or prevent the growth of microorganisms that arise in the wound so not cause severe infections. Many research have been conduct to investigate the ability of Siam weed in wound healing, for example previous study reported that 5.0% (w/w) *Chromolaena odorata* ethanol extract are effective for excision wound healing which exhibited a faster reduction in wound area compared to control and

Betadine-treated group<sup>17</sup>. The efficacy of 2.5%, 5%, and 10% w/w of Siam weed leaves extract ointments on cutaneous wound being conducted and proved the ability of inducing wound contraction and wound closure time. Another experimental using Siam Weed leaves, which prepared in cream with a concentration of 2.5%, 5% and 10% and applied in open wounds in experimental animals<sup>18</sup>. The percentage of wound healing represented as an average wound diameter showed that the ethanol extract of Siam weed leaves with a concentration of 10% gave wound healing effect faster compared to povidone iodine that used as a control drug<sup>18</sup>. The application of Siam weed extract on excision wound also prove the effectiveness of this plant on wound healing time and repairment of the wounded tissue<sup>17</sup>.

To strengthen the effectiveness of Siam weed wound healing properties, this study aims to see the potential of Siam weed leaves in ointment base which applied in burn wound on *Rattus norvegicus*. The parameter value that used was wound diameters or epidermal growth factor and the number of neutrophils. Anti-inflammatory assay using 5-lipoxygenase and antioxidant assay using Ferric-Reducing Antioxidant Power (FRAP assay) were conducted to support wound healing efficacy.

## MATERIALS AND METHODS:

### Materials:

Human recombinant 5-lipoxygenase enzyme and nordihydroguaiaretic acid (NDGA) were purchased from Calbiochem, Sandiego, TPTZ (2,4,6-tripyridyl-s-triazine), NDGA, quercetin, folin-Ciocalteu's and linoleic acid, were purchased from Sigma, Germany. Other materials used for this research were analytical grade.

### Preparation and phytochemical screening of ethanol extract of Siam weed leaves:

Fresh leaves of the Siam weed (*Chromolaena odorata* L.) was collected from Surabaya, East Java and determined as a herbarium specimen (HBP/WMCUS/345/CO) at Botany Pharmacy laboratory Widya Mandala Surabaya Catholic University. Leaves were dried in the laboratory approximately for 2 weeks at room temperature. Dried powder of Siam weed leaves with the amount of 250 gram was macerated using 2500 mL 96% ethanol as solvent. Macerates were evaporated using a rotary evaporator until dried extract was obtained. The phytochemical screening using tube method was conducted to find out the chemical compounds of ethanol extract of Siam weed leaves<sup>(19)</sup>. Thin Layer chromatographic profile is also being conducted to ensure the quality control of Siam Weed leaves ointment. Dried extract kept in -20° C freezer until next biological assay was conducted.

### Preparation of Siam weed ointment:

Vaseline album and adepslanae with the portion of 17:3 were prepared for ointment base. The preparation was done by melting the adepslanae and Vaseline album in hot mortar, than the amount of the ethanol extract of Siam weed leaves was added (Table 1). The ointment stirred continuously until all ingredients were homogenously mixed. The ointment is kept in 4°C not longer than 1 week. All the ointments are evaluated for the homogeneity and pH to ensure the efficacy and the safety.

**Table 1: Ointment formulations of ethanol extract of Siam weed (*Chromolaena odorata* L.)**

Materials	5% Ethanol extract of Siam weed (g)	10% Ethanol extract of Siam weed (g)
Ethanol extract of Siam weed	1.50	3
Ointment base	28.50	27

### Second- degree burn wound induction procedural<sup>20</sup>

Twenty four healthy male wistar white rats with average weight of 150 - 200grams, healthy, no abnormalities or physical disabilities been used for this research. The experimental animals were divided into 4 groups randomly, namely: negative control (C-, burn wound induced, given paracetamol), positive control (C+, burn wound induced, Bioplacenton was applied to burn wound), 2 treatment groups (burn wound induced, P1: Siam weed ethanol extract 5% was applied to burn wound; and P2: Siam weed ethanol extract 10% was applied to burn wound). The fur on the dorsal / back of the rat was shaved and then the dorsal area with no fur sterilized with 70% alcohol. The rats were then anesthetized and burns were induced by sticking a hot rod for 30 second. The hot rod with the size of 2 x 2 cm prepared by preheated in a water bath for 5 minutes at 95°C. Each experimental animal group was given treatment for 7 days. This experiment carried out in accordance with laboratory animal ethics guidelines.

### Burn wound diameter measurement<sup>21</sup>

The wound diameter was measured daily using a caliper. The procedure to measure burn wound diameters can be seen in Figure 1. The burn wound diameters calculated using this formula:

$$d \times = \frac{D \times 1 + d \times 2 + d \times 3 + d \times 4}{4}$$

dx: Burn wound diameter; dx1: Burn wound diameter 1; dx2: Burn wound diameter 2; dx3: Burn wound diameter 3; dx4: Burn wound diameter 4

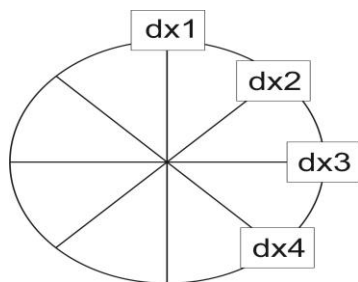


Figure 1: Measurement procedures for burn wound diameter

#### Observation of Neutrophil Count in burn wound<sup>22</sup>

Observation of the number of neutrophil cells was carried out on day 3 and day 7 using a Nikon H600L light microscope equipped with a 300 megapixel DS Fi2 digital camera with image processing software Nikon Image System. Observations of the rat skin tissue were made by taking five different fields of view using 1000x magnification. The rat skin tissue was stained using Hematoxylin Eosin (HE). The number of inflammatory cells observed in each field of view was add up and presented as an average value.

#### Anti-inflammatory assay:

5-Lipoxygenase enzyme assay was used to determine the anti-inflammatory activity of the ethanol extract of Siam weed using linoleic acid as the substrate. In one mL cuvette which is maintained at 25 °C was added 970  $\mu$ L of phosphate buffer (pH 9) than 5  $\mu$ L (50 mg/mL) extract and followed by 17  $\mu$ L of linoleic acid. Sample was shaking and 4  $\mu$ L of the aliquot enzyme followed by 4  $\mu$ L of the phosphate buffer (4°C) were pipetted to initiate enzyme reaction. The sample absorbance measured at  $\lambda$ : 234 nm for 10 minutes using spectrophotometer. Aspirin and Nordihydroguaiaretic acid (NDGA) were used as the positive control. The percentage activity was determined using the slopes of the straight-line portions of the sample and the control curves<sup>23</sup>.

#### Ferric-reducing antioxidant power (FRAP) assay:

The antioxidant assay was conducted using FRAP assay with the following step: FRAP reagent was prepared freshly by mixing 300 mM acetate buffer (pH 3.6) with 10mM 2,4,6-tripyridyl-s-triazine (TPTZ) and 20mM  $\text{FeCl}_3 \cdot 6\text{H}_2\text{O}$  (1:10:1). FRAP reagent 180 $\mu$ L mixed with 20 $\mu$ L sample. Sample was prepared with the concentration of 1 mg/mL - 0.03mg/mL. The absorbance was read at 90 minutes ( $\lambda$ : 600nm) using spectrophotometer (Thermostat, Finland, USA). The standard, Fe (II) was prepared with the concentrations in the range 1 $\mu$ M – 125  $\mu$ M ( $\text{FeSO}_4 \cdot 7\text{H}_2\text{O}$ ). Quercetin was used as a positive control. The antioxidant value, represent as a FRAP value was calculated as Ferrous Equivalents. This Ferrous equivalent produced the concentration of quercetin/sample that gave the absorbance value equal to that 1 mM  $\text{FeSO}_4$ .<sup>24,25</sup>

#### Data Analysis:

The results are presented as mean $\pm$ SEM. The data obtained from the measurement of wound diameter, the number of neutrophil cells, anti-inflammatory and antioxidant activities were analyzed using One-Way ANOVA. Significance degree used in this analyze is p 0.05 with 95% confidence interval. Post Hoc Duncan test used for further investigation.

#### RESULTS:

##### Phytochemical screening Results:

In the formulation of herbal products, a screening/ chromatographic profile of active chemical components is needed to ensure the quality of a natural product. In this study, phytochemical screening was carried out on dried powder, ethanol extract and ointment from Siam weed leaves. Preliminary screening was carried out using the tube method to investigate the presence of alkaloids, flavonoids, polyphenols, saponins, tannins, steroids and triterpenoids. Chromatographic profile of thin layer chromatography was carried out using chloroform: ethyl acetate (15:1) as a mobile phase and vanillin sulphuric acid as a visualization reagent (Figure 2). The phytochemical results of Siam weed leaves ethanol extract showed the presence of alkaloids, polyphenols, flavonoids, saponins, tannins and steroids (Table 2).

Table 2: Phytochemical screening results of ethanol extract of Siam weed leaves using tube methods

Compounds	Dried powder	Ethanol extract	Ointment of Siam weed
Alkaloid	+	+	+
Flavonoid	+	+	+
Polyphenol	+	+	+
Saponin	+	+	+
Tannin	+	+	+
Steroid	+	+	+
Triterpenoid	+	+	+

The presence (+) or absence (-) compounds were detected using reagents that describe in common procedures<sup>19,26</sup>


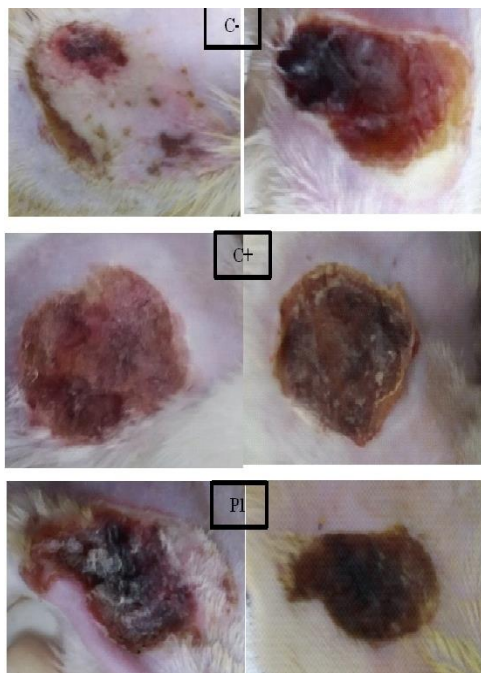


Figure 2: Chromatographic profile of TLC of Siam Weed leaves (*Chromolaena odorata*) using mobile phase Chloroform: Ethyl Acetate (15:1).

1= Dried powder 10% in methanol (spotted 20 $\mu$ L); 2= ethanol extract 1% (spotted 20 $\mu$ L); 3= ointment of Siam Weed 10% (spotted 20 $\mu$ L); a= observation at UV 254 nm; b= observation at UV 366nm; c = after being sprayed with Vanillin sulphuric acid spray reagent.

### Burn wound diameter analysis:

The healing process represented as a measurement of burn wound diameters results can be seen in Table 3 and Figure 3. The results showed there was a significant difference ( $p < 0.05$ ) in wound diameter between the treatment groups and no treatment group. Tremendously, the 10% ointment Siam weed accelerate the healing process showed by the decreasing burn wound diameter as much as the standard drug ( $\pm 0.36$  cm) that is used in this treatment. The present of festering wound observe in C(-) groups indicates the infection happening in the group with no treatment. There was no infection present in the treatment group. It showed that the samples (bioplacenton or ointment of Siam weed) can protect the wound which can result in the absence of bacterial growth. Based on the results, 5% and 10% Siam Weed ointment was able to reduce wound diameter by 26% and 28%, respectively.



**Figure 3:** The observation results on burn wound in experimental animals

C(-): negative control, burn wound induced, given paracetamol; C(+): positive control, burn wound induced, Bioplacenton was applied to burn wound; P1: burn wound induced, Siam weed ethanol extract 5% was applied to burn wound; P2: burn wound induced, Siam weed ethanol extract 10% was applied to burn wound. Left side: the observation result on day 3; Right side: the observation result on day 7

**Table 3: Average burn wound diameters**

Treatment Groups*	Average burn wound diameters $\pm$ SD (cm) on day 3	Average burn wound diameters $\pm$ SD (cm) on day 7
C(-)	$1.95 \pm 0.04^b$	$1.78 \pm 0.01^b$
C(+)	$1.89 \pm 0.07^{ab}$	$1.53 \pm 0.04^a$
P1	$1.79 \pm 0.09^a$	$1.49 \pm 0.07^a$
P2	$1.82 \pm 0.03^a$	$1.44 \pm 0.05^a$

Different superscripts in the same mean column show significant differences between treatment groups ( $p < 0.05$ ).

\*C(-): negative control, burn wound induced, given paracetamol; C(+): positive control, burn wound induced, Bioplacenton was applied to burn wound; P1: burn wound induced, Siam weed ethanol extract 5% was applied to burn wound; P2: burn wound induced, Siam weed ethanol extract 10% was applied to burn wound.

### Neutrophil Count in burn wound analysis:

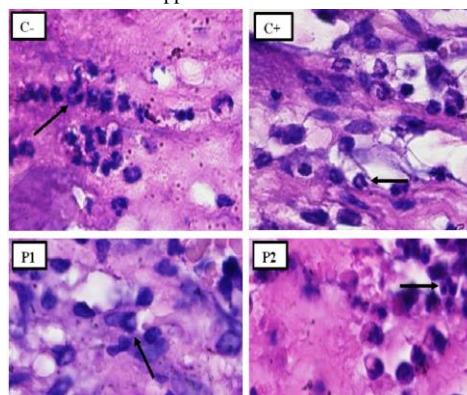
Neutrophils, one of the immune system responses take part of the first line of defence in tissue damage or infection<sup>27</sup>. Burn wound can result in amount of the neutrophils in response to wounding. The number of neutrophil in C(-) group on day 3 which still increasing in day 7 showed that there was an infection going on, proved with festering wound that occurred in day 7. Ten % ointment of Siam weed gave no significant difference with the control drug in term of decreasing the number of neutrophils (Table 4 and Figure 4).

**Table 4: The average of the number of neutrophil**

Treatment Groups	The average of the number of neutrophil $\pm$ SD on day 3	The average of the number of neutrophil $\pm$ SD on day 7
C(-)	$134.67 \pm 0.75^{ab}$	$141.67 \pm 0.33^a$
C(+)	$105.00 \pm 0.33^a$	$87.00 \pm 0.93^a$
P1	$101.33 \pm 0.71^a$	$100.67 \pm 0.31^a$
P2	$108.67 \pm 0.26^b$	$85.67 \pm 0.66^a$

Different superscripts in the same mean column show significant differences between treatment groups ( $p < 0.05$ ).

\*C(-): negative control, burn wound induced, given paracetamol; C(+): positive control, burn wound induced, Bioplacenton was applied to burn wound; P1: burn wound induced, Siam weed ethanol extract 5% was applied to burn wound; P2: burn wound induced, Siam weed ethanol extract 10% was applied to burn wound.



**Figure 4:** Neutrophil Cells (black arrows) observed under a light microscope (Nikon H600L microscope; camera DS Fi2 300 megapixels) with magnification 1000x

C(-): negative control, burn wound induced, given paracetamol; C(+): positive control, burn wound induced, Bioplacenton was applied to burn wound; P1: burn wound induced, Siam weed ethanol extract 5% was applied to burn wound; P2: burn wound induced, Siam weed ethanol extract 10% was applied to burn wound.

### Anti-inflammatory and antioxidant analysis:

Inflammatory response in burn wound normally occurring with free radicals in inflammation site which caused cell damages and could postpone the healing process<sup>28</sup>. It's already well known that tissue damage, including burn wound can be caused by oxidative stress and some previous study make a linier correlation between the potency of wound healing agents with antioxidant activity. Based on the results, it showed that Siam weed leaves ethanol extract gave strong antioxidant capacity with the FRAP value (1.16 mmol/L) even greater compared to quercetin (Table 5). The ethanol extract of Siam weed leaves showed weaker anti -inflammatory activity compared to Aspirin and NDGA that use for standard, but nevertheless with IC<sub>50</sub> 5-LOX 55.01µg/mL, Siam weed leaves showed the potential can be used for anti-inflammatory agents.

**Table 5: IC<sub>50</sub> 5-LOX values and FRAP value of Crude extract of Siam Weed**

Samples	IC <sub>50</sub> 5-LOX values (µg/mL)	FRAP value (mmol/L)
Ethanol extract of Siam weed leaves	55.01 ± 0.04	1.16 ± 0.13
NDGA	5.33 ± 0.05	--
Aspirin	13.90 ± 0.07	--
Quercetin	--	1.31 ± 0.02

Data were obtained from 3 independent experiments, each performed in triplicate (n=9) and represented as mean ± SEM.

IC<sub>50</sub> represents the effective concentration at 50% of total inhibition of 5- lipoxygenase activity.

NDGA: Nordihydroguaiaric acid; FRAP value was calculated as Ferrous Equivalents, the concentration of quercetin or extracts which produced an absorbance value equal to that of 1 mmol/L of Fe<sub>2</sub>SO<sub>4</sub>

### DISCUSSIONS:

*Chromolaena odorata*, considered as one of the top 100 most invasive environmental weeds, native from North and Central America, now a days mostly found abundantly in Indonesia. This weed well known for its pesticide properties, the potency for the treatment of almost all kinds of wounds type, treatment of leech bites, indigestion, skin infection, fungicidal, analgesic, antispasmodic, anti-inflammatory, antipyretic, insecticidal, antioxidant, anti-gonorrhoeal, diuretic and antimicrobial<sup>17,18,29,30</sup>.

In this experiment, the maceration process of Siam weed leaves produced 62.7grams extracts with a yield of 25.08%. The ethanol extract of Siam weed leaves gave blackish brown in color and distinctive smells of herbs. The ointment base was selected for the preparation of the medicine to cover the difficulties polar compounds to penetrate the skin layer. The Siam weed ointment with the concentration of 5% and 10% performance as a dark green-black semi solid sample, have a distinctive herbs smell, homogeneous, and have a pH value that meets the requirement of skin pH criteria, which is between 4.5-6.5<sup>31</sup>.

In this research, second-degree burn was induced in experimental animals. This type of burn wound was involved the first two layer of the skin and was common accident in the house hold. The applied of 5 % and 10% of Siam weed ointment accelerate the wound healing ability which are shown by the decreasing of burn wound diameter, decreasing healing time showed by the dryness and no festering wounds in burn wound, and the decreasing the number of neutrophils. In the negative control, paracetamol as an analgesic was given in animal treatment to reduce the pain caused by burn wound induced. Experimental research showed that paracetamol does not compromised to wound repair, so the given of paracetamol will not affect to experimental results<sup>32</sup>.

Based on the results, it is suggested that Siam weed promote the migration and proliferation of fibroblast cell that can stimulate wound healing properties and haemostatic process<sup>9</sup>. No festering wound found in the treatment groups suggested the result supported the previous research, where Siam weed ethanol extract has the antibacterial activities against both Gram-positive and Gram-negative bacteria such as *Staphylococcus aureus*, *Pseudomonas aeruginosa*, *Bacillus cereus*, *Bacillus subtilis*, and *Escherichia coli*, suggesting that it may reduce the wound infections<sup>33-36</sup>.

In – vitro anti-inflammatory effect was also observed in this study. Some of evidence suggested that the anti-inflammatory action of Siam weed produced by the fatty acids components that contain in Siam weed. The previous research showed reduces oedema and exudates, where wound healing can subsequently improve. The reducing of the amount of prostaglandin that produced in inflammatory process also suggested the reducing in pain<sup>37,38</sup>.

The ability of Siam weed to scavenge free radicals enhances the efficiency of wound healing by conserving the fibroblast and keratinocyte proliferation on wounds<sup>39</sup>, therefore it proved in this research burn wound in treatment group no infected wound appeared cause of keratinocytes proliferated to cover the wound.

The phytochemical results of Siam weed leaves ethanol extract showed the presence of alkaloids, polyphenols, flavonoids, saponins, tannins and steroids. Chromatographic profiles using TLC were performed on dried powder, ethanol extract and Siam Weed ointment. The results indicated a stain profile with the same Rf value and color (Figure 2). The result shows that during the extraction and formulation of Siam Weed ointment, there is no process that influences the presence of active compounds in Siam weed.



In nature, flavonoids as anti-inflammatory inhibit the lipoxygenation pathway which will release inflammatory mediators, and also inhibit the arachidonic acid pathway by inhibiting COX-2 expression. The impact of this decrease in COX-2 is a decrease in the number of prostaglandins, especially in the pro-inflammatory mediator PGE<sub>2</sub>, causing a reduction in the inflammatory reaction<sup>40,41</sup>. As an antibacterial, flavonoids form complex compounds against extracellular proteins that disrupt the integrity of the bacterial cell membrane. Flavonoids also work as antioxidants by preventing oxidation and also enhancing migration and proliferation of fibroblast<sup>42</sup>. Saponins have the ability as cleansers and antiseptics that function to kill or prevent the growth of microorganisms that arise in the wound so that the wound does not experience severe infection<sup>43</sup>. Steroids function as anti-inflammatory which can prevent stiffness and pain<sup>44</sup>. Steroid compounds also have anti-inflammatory properties like flavonoids but have a slower wound healing effect than flavonoids<sup>43</sup>.

## CONCLUSIONS:

Ointment of 10% Siam weed ethanol extract has burn wound healing properties by assessment to its reducing wound diameter and the number of neutrophils in the healing process of burns in rats. The burn wound healing property is supported by antioxidant and anti-inflammatory activity by inhibiting the inflammatory mediators. No festering wound found suggesting Siam weed can inhibit the growth of bacteria that can cause infections.

## CONFLICT OF INTEREST:

The authors have no conflicts of interest regarding this investigation.

## ETHICAL APPROVAL:

All applicable international, national, and/or institutional guidelines for the care and use of animals were followed.

## REFERENCES:

- Bhatia N, Singh A, Sharma R, Singh A, Soni V, Singh G, et al. Evaluation of burn wound healing potential of aqueous extract of *Morus alba* based cream in rats. *J Phytopharm*. 2014; 3(6): 378–83. doi:10.31254/phyto.2014.3601
- Yuniarti WM, Lukiswanto BS. Effects of herbal ointment containing the leaf extracts of Madeira vine (*Anredera cordifolia* (Ten.) Steenis) for burn wound healing process on albino rats. *Vet World*. 2017; Jul; 10(7): 808–13. doi: 10.14202/vetworld.2017.808-813
- Zheng W, Zhao DL, Zhao YQ, Li ZY. Effectiveness of platelet rich plasma in burn wound healing: a systematic review and meta-analysis. *J Dermatol Treat*. 2022; Feb; 33(1): 131–7. doi: 10.1080/09546634.2020.1729949
- Rowan MP, Cancio LC, Elster EA, Burmeister DM, Rose LF, Natesan S, et al. Burn wound healing and treatment: review and advancements. *Crit Care*. 2015; 19: 243. doi: 10.1186/s13054-015-0961-2
- Guo X, Liu Y, Bera H, Zhang H, Chen Y, Cun D, et al.  $\alpha$ -Lactalbumin-Based Nanofiber Dressings Improve Burn Wound Healing and Reduce Scarring. *ACS Appl Mater Interfaces*. 2020; Oct 14; 12(41): 45702–13. <https://doi.org/10.1021/acsami.0c05175>
- Wang Y, Beekman J, Hew J, Jackson S, Issler-Fisher AC, Parungao R, et al. Burn injury: Challenges and advances in burn wound healing, infection, pain and scarring. *Adv Drug Deliv Rev*. 2018; 123(January): 3–17. <https://doi.org/10.1016/j.addr.2017.09.018>
- Sirinthipaporn A, Jiraungkoorskul W. Wound Healing Property Review of Siam Weed, *Chromolaena odorata*. *Pharmacogn Rev*. 2017; 11(21): 35–8. doi: 10.4103/phrev.phrev\_53\_16
- Vijayaraghavan K, Rajkumar J, Seyed MA. Efficacy of *Chromolaena odorata* leaf extracts for the healing of rat excision wounds. *Veterinarni medicina*. 2017; 62(10): 565–578. <https://doi.org/10.20956/ijab.v3i1.5868>
- Pandith H, Zhang X, Thongpraditchote S, Wongkrajang Y, Gritsanapan W, Baek SJ. Effect of Siam weed extract and its bioactive component scutellarein tetramethyl ether on anti-inflammatory activity through NF- $\kappa$ B pathway. *J Ethnopharmacol*. 2013; May 20; 147(2): 434–41. doi: 10.1016/j.jep.2013.03.033
- Aziz NA, Mohamad M, Mohsin HF, Hazalin NAMN, Hamid KA. The Pharmacological Properties and Medicinal Potential of *Chromolaena odorata*: A Review. *Int J Pharm Nutraceuticals Cosmet Sci*. 2020; 2: 30–41. <https://ir.uitm.edu.my/id/eprint/70691/3/70691.pdf>
- Sittikijyothin W, Phonyotin B, Sangnim T, Huanbutta K. Using carboxymethyl gum from *Tamarindus indica* and *Cassia fistula* seeds with *Chromolaena odorata* leaf extract to develop antibacterial gauze dressing with hemostatic activity. *Res. Pharm. Sci*. 2021; Mar 5; 16(2): 118–28. doi: 10.4103/1735-5362.310519
- Rajkumar RJ, Nadar M, Selvakumar PM. Phytochemicals as a potential source for anti-microbial, anti-oxidant and wound healing - a review. *Bioorganic Org Chem*. 2018; 2(2): 61–70. doi:10.15406/mojboc.2018.02.00058
- Ezenyi IC, Salawu OA, Kulkarni R, Emeje M. Antiplasmodial activity-aided isolation and identification of quercetin-4'-methyl ether in *Chromolaena odorata* leaf fraction with high activity against chloroquine-resistant *Plasmodium falciparum*. *Parasitol Res*. 2014; Dec 1; 113(12): 4415–22. doi:10.1007/s00436-014-4119-y
- Emani L, Ravada S, Meka B, Garaga M, Golakoti T. A New Flavonone from the Leaves of *Chromolaena odorata*. *Nat Prod Commun*. 2015; Sep; 10(9): 1555–9. doi:10.1177/1934578x1501000918
- Hanafiah OA, Abidin T, Ilyas S, Nainggolan M, Syamsudin E. Wound Healing Activity of Binahong (*Anredera cordifolia* (Ten.) Steenis) Leaves Extract towards NIH-3T3 Fibroblast Cells. 2019 [cited 2023 May 24]; Available from: <https://dupakdosen.usu.ac.id/handle/123456789/3997>
- Irfham WH, Tamrin, Marpaung L, Marpongahtun. Bioactive Compounds In Pegagan Leaf (*Centella asiatica* L. Urban) for Wound Healing. *J Phys Conf Ser*. 2019; Sep; 1232(1): 012019. doi:10.1088/1742-6596/1232/1/012019
- Vijayaraghavan K, Rajkumar J, Bukhari SNA, Al-Sayed B, Seyed MA. *Chromolaena odorata*: A neglected weed with a wide spectrum of pharmacological activities (Review). *Mol Med Rep*. 2017; Mar 1; 15(3): 1007–16. doi:10.3892/mmr.2017.6133
- Amaliah UN, Johannes E, Hassan MS, Tambaru E. The Use Extract of Siam Leaf *Eupatorium odoratum* L. as Alternative Material In Lowering Blood Glucose. *Int J Appl Biol*. 2019; 3(1): 15–23. <https://doi.org/10.20956/ijab.v3i1.5868>
- Dinakaran SK, Chelle S, Avasarala H. Profiling and determination of phenolic compounds in poly herbal formulations and their comparative evaluation. *J Tradit Complement Med*. 2019; Oct 1; 9(4): 319–27. doi:10.1016/j.jtcme.2017.12.001
- Vaghardoost R, Mousavi Majd SG, Tebyanian H, Babavalian H, Malaei L, Niazi M, et al. The Healing Effect of Sesame Oil, Camphor and Honey on Second Degree Burn Wounds in Rat.

- World J Plast Surg. 2018; Jan; 7(1): 67–71. PMID: PMC5890368 available on <https://pubmed.ncbi.nlm.nih.gov/29651394/>
21. Yaghoobi R, Kazerouni A, Kazerouni O. Evidence for Clinical Use of Honey in Wound Healing as an Anti-bacterial, Anti-inflammatory Anti-oxidant and Anti-viral Agent: A Review. Jundishapur J Nat Pharm Prod. 2013; Aug; 8(3): 100–4. doi: 10.17795/jjnpp-9487
22. Muhammad K, Prasetyo A, Prajoko YW, Najatullah N, Susilaningih N. Effectiveness of nanosilver collagen cream for healing deep dermal burns in Sprague Dawley rats: an overview of neutrophil counts and angiogenesis. Bali Med J. 2021; Jul 26; 10(2): 648–52. <https://doi.org/10.15562/bmj.v10i2.2313>
23. Che Zain MS, Lee SY, Sarian MN, Fakurazi S, Shaari K. In Vitro Wound Healing Potential of Flavonoid C-Glycosides from Oil Palm (*Elaeis guineensis* Jacq.) Leaves on 3T3 Fibroblast Cells. Antioxidants. 2020; Apr 17; 9(4): 326. doi: 10.3390/antiox9040326
24. Parit SB, Dawkar VV, Tanpure RS, Pai SR, Chougale AD. Nutritional Quality and Antioxidant Activity of Wheatgrass (*Triticum aestivum*) Unwrap by Proteome Profiling and DPPH and FRAP assays. J Food Sci. 2018; 83(8): 2127–39. doi:10.1111/1750-3841.14224
25. Rangasamy P, Hansiya VS, Maheswari PU, Suman T, Geetha N. Phytochemical Analysis and Evaluation of In vitro Antioxidant and Anti-urolithiatic Potential of various fractions of *Clitoria ternatea* L. Blue Flowered Leaves. Asian J Pharm Anal. 2019; May 11; 9(2): 67–76. doi:10.5958/2231-5675.2019.00014.0
26. Ratnasooriya WD, Pathirana RN, Gamage RNN, Hasanthi KB, Hettihewa SK. In vitro sunscreen activity of Methanolic root extract of a Sri Lankan grass *Heteropogon contortus*. Asian J Pharm Anal. 2018; Jun 11; 8(2): 65–8. doi:10.5958/2231-5675.2018.00012.1
27. Hemmati A, Namjuyan F, Yousefi S, Housmand G, Khadem Haghighian H, Rezaei A. The Healing Effect of N-Hexan-Dichloromethane Extract Root *Onosma bulbosum* in Second Degree Burns. World J Plast Surg. 2018; Jan; 7(1): 25–33. PMID: PMC5890363 available on <https://pubmed.ncbi.nlm.nih.gov/29651389/>
28. Heidari M, Bahramsoltani R, Abdolghaffari AH, Roja R, Mohammadamin E, Baeri M. *Chromolaena odorata* - an overview | Science Direct Topics. 2019. <https://doi.org/10.1016/B978-0-323-90999-0.00015-X>. available on <https://www.sciencedirect.com/topics/agricultural-and-biological-sciences/chromolaena-odorata>
29. Svecnjak L, Marijanović Z, Okieńczyk P, Marek Kuś P, Jerković I. Mediterranean Propolis from the Adriatic Sea Islands as a Source of Natural Antioxidants: Comprehensive Chemical Biodiversity Determined by GC-MS, FTIR-ATR, UHPLC-DAD-QqTOF-MS, DPPH and FRAP Assay. Antioxidants. 2020; Apr; 9(4): 337. <https://doi.org/10.3390/antiox9040337>
30. von Muller C, Bulman F, Wagner L, Rosenberger D, Marolda A, Kurzai O, et al. Active neutrophil responses counteract *Candida albicans* burn wound infection of ex vivo human skin explants. Sci Rep. 2020; Dec 11; 10(1): 21818. doi:10.1038/s41598-020-78387-y
31. Proksch E. pH in nature, humans and skin. J Dermatol. 2018; 45(9): 1044–52. doi:10.1111/1346-8138.14489
32. Borges A, Abreu AC, Dias C, Saavedra MJ, Borges F, Simões M. New Perspectives on the Use of Phytochemicals as an Emergent Strategy to Control Bacterial Infections Including Biofilms. Mol Basel Switz. 2016; Jul 5; 21(7): 877. doi:10.3390/molecules21070877
33. Omeke PO, Obi JO, Orabueze NAI, Ike AC. Antibacterial activity of leaf extract of *Chromolaena odorata* and the effect of its combination with some conventional antibiotics on *Pseudomonas aeruginosa* isolated from wounds. J Appl Biol Biotechnol. 2019; 7(3): 36–40. doi: 10.7324/JABB.2019.70307
34. Adewumi Alabi M, Olusola-Makinde O, Kolawole Oladunmoye M. Evaluation of Phytochemical Constituents and Antibacterial Activity of *Chromolaena odorata* L. Leaf Extract against Selected Multidrug Resistant Bacteria Isolated from Wounds. South Asian J Res Microbiol. 2020; Jan 21; 5(3): 1–9. doi:10.9734/sajrm/2019/v5i330132
35. Aulia A, Umam K. Antibacterial Screenings of *Chromolaena odorata* L. and its potential against *Staphylococcus aureus*, *Bacillus subtilis*, *Staphylococcus typhimurium*, and *Escherichia coli* in Sumbawa. J Biol Trop. 2022; Sep 30; 22(3): 1077–83. doi:10.29303/jbt.v22i3.4220
36. Rasyid SA, Sugireng, Surya RA, Sanatang, Rosdarni, Natalisa WOR. The antibacterial activity of Tembelekan leaf (*Lantana camara* L.) and Kopasanda leaf (*Chromolaena odorata* L.) extracts against *Staphylococcus aureus*. Infect Dis Rep. 2020; 12(1): 65–7. doi:10.4081/idr.2020.8734
37. Elion Itou RDG, Etou Ossibi AW, C E, Nsondi Ntandou GF, Bokia CB, Ouamba JM, et al. Anti-inflammatory and analgesic effects of leaves of *Chromolaena odorata* L. (King and Robinson). Afr J Pharm Pharmacol. 2017; May 8; 11(17): 217–23. <https://doi.org/10.5897/AJPP2017.4753>
38. Cahyo ASD, Oktavia S, Ifora I. Anti-Inflammatory and Analgesic Potential of *Chromolaena odorata*: A Review. Int J Pharm Sci Med. 2021; Sep 30; 6(9): 8–16. doi:10.47760/ijpsm.2021.v06i09.002 available on <https://ijpsm.com/Publish/Sep2021/V6I902.pdf>
39. Olawale F, Olofinson K, Iwaloye O. Biological activities of *Chromolaena odorata*: A mechanistic review. South Afr J Bot. 2022; Jan 1; 144: 44–57. <https://doi.org/10.1016/j.sajb.2021.09.001>
40. Meena AK, Rao MM, Meena RP, Panda P, Renu. Pharmacological and Phytochemical Evidences for the Plants of *Wedelia* Genus– A Review. Asian J. Pharm. Res. 2011; Mar 28; 1(1): 07–12. available on <https://asianjpr.com/HTMLPaper.aspx?Journal=Asian%20Journal%20of%20Pharmaceutical%20Research;PID=2011-1-1-2>
41. Kp J, Kumar A, D VB, V.b NS. Studies on Anti-depressant and Anti-inflammatory Activities of *Curcuma aromatica* Rhizome in Experimental Animal Models. Asian J. Pharm Res. 2016; Jun 28; 6(2): 79–86. doi:10.5958/2231-5691.2016.00014.9.
42. Gulcicek OB, Solmaz A, Yigitbas H, Ercetin C, Yavuz E, Ozdogan K, et al. Role of diclofenac sodium and paracetamol on colonic anastomosis: An experimental rodent model. Asian J Surg. 2018; May 1; 41(3): 264–9. doi:10.1016/j.asjsur.2017.01.002
43. Vijayaraghavan K, Rajkumar J, Seyed MA. Phytochemical screening, free radical scavenging and antimicrobial potential of *Chromolaena odorata* leaf extracts against pathogenic bacterium in wound infections– a multispectrum perspective. Biocatal Agric Biotechnol. 2018; Jul 1; 15: 103–12. <https://doi.org/10.1016/j.bcab.2018.05.014>
44. Fahim AZM, Ghouse MS, Islam SQ, Danish MAM, Mehmood S, Saniya S, et al. Isolation and Identification of Boswellic Acids by Modern Analytical Techniques. Asian J Pharm Anal. 2021; May 13; 11(2): 98–112. doi: 10.52711/2231-5675.2021.00018