

## REVIEW ARTICLE: UNDERSTANDING EPISTAXIS, CLINICAL EVALUATION, AND STEPWISE MANAGEMENT

Widia Isa Aprillia Sujana<sup>1</sup>, Julian Hartawan Wijaya<sup>2</sup>

\*Corresponding author email: [widia@ukwms.ac.id](mailto:widia@ukwms.ac.id)

DOI: <https://doi.org/10.33508/jwmj.v8i1.7946>

### ABSTRACT

*Epistaxis, derived from the Greek term epistazein, refers to bleeding originating from the nasal cavity or nasopharynx and represents one of the most common emergencies encountered in otolaryngology. Approximately 60% of the global population experiences epistaxis at least once during their lifetime; however, only a small proportion require medical intervention. The clinical severity ranges from self-limiting anterior bleeding to life threatening hemorrhage, particularly in patients with cardiovascular disease, coagulation disorders, or platelet dysfunction. Etiologically, epistaxis is classified into local, systemic, or idiopathic causes and demonstrates a bimodal age distribution, predominantly affecting children and adults older than 50 years. Anterior epistaxis, most commonly arising from Kiesselbach plexus, accounts for the majority of cases and is typically mild and self-limited. In contrast, posterior epistaxis occurs less frequently but is often associated with greater morbidity and higher hospitalization rates. Initial evaluation prioritizes airway protection and hemodynamic stabilization, followed by focused history taking, physical examination, and selective laboratory investigations when indicated. Management strategies range from conservative measures, including digital nasal compression, topical vasoconstrictors, tranexamic acid administration, chemical cauterization, and nasal packing to more invasive interventions such as endoscopic cauterization, arterial ligation, or endovascular embolization in refractory or severe cases. Advances in endoscopic techniques and the development of absorbable nasal packing materials have improved treatment efficacy, enhanced patient comfort, and reduced complication rates. **Conclusion:** Epistaxis is a common otolaryngologic emergency with a broad spectrum of clinical severity. Although most cases can be managed conservatively, a comprehensive understanding of its etiology, vascular anatomy, and stepwise management is essential to optimize outcomes and minimize morbidity and mortality.*

**Keywords:** Clinical evaluation; Epistaxis; Stepwise management

Article history: Received 2025-12-11, Revised 2026-03-13, Accepted 2026-03-20, Online 2026-03-20

### INTRODUCTION

Epistaxis is derived from the Greek word “epistazein”, which describes bleeding from the nose, consists of two words: “epi” that means inside and “stein”, meaning drip. Epistaxis is one of the most common ENT emergencies, ranging from minor bleeding with clot formation to massive, life-threatening bleeding. Epistaxis occurs in approximately 60% of the global population at least once in a lifetime. Ten percent of epistaxis cases require medical attention, and only 0.5 to 1% require evaluation by an otolaryngologist. Most of the time, bleeding stops with topical oxymetazoline and

digital compression of the nose, and 6% require further treatment. Uncontrolled epistaxis is life-threatening if not treated promptly and appropriately. Treatment is difficult in patients with cardiovascular disease, coagulation disorders, or platelet dysfunction.<sup>1-4</sup>

This narrative review aims to provide a comprehensive overview of epistaxis, including its epidemiology, etiology, pathophysiology, clinical evaluation, and current management strategies, in order to support effective diagnosis and evidence-based treatment in clinical practice.

<sup>1</sup> Department of Otorhinolaryngology, Faculty of Medicine, Widya Mandala Surabaya Catholic University, Surabaya, Indonesia.

<sup>2</sup> Department of Otorhinolaryngology, Faculty of Medicine, Widya Mandala Surabaya Catholic University, Surabaya, Indonesia.

## METHODS

This narrative review was conducted to summarize current knowledge regarding epistaxis and its clinical management. Literature was identified through electronic database searches including PubMed, Scopus, and Web of Science.

Search terms included a combination of the following keywords: epistaxis, nosebleed, nasal bleeding, epistaxis management, epistaxis treatment, and nasal vascular anatomy. Articles published in English and relevant to the epidemiology, pathophysiology, diagnosis, and management of epistaxis were prioritized. Preference was given to studies published within the last 10 years, although earlier landmark studies were also included when relevant.

Both original research articles and review articles were considered. Studies were selected based on relevance to clinical practice, methodological quality, and their contribution to the understanding of epistaxis. The collected literature was then analyzed and synthesized thematically to provide a comprehensive overview of current evidence regarding epistaxis.

## DISCUSSION

### Definition

Epistaxis is defined as active bleeding from the nasal cavity or nasopharynx.<sup>5-7</sup>

### Etiology

The causes and risk factors of epistaxis can be broadly classified into local, systemic, and idiopathic factors. Local causes include low environmental humidity, trauma, intranasal medications, infection, inflammation, and tumors. Systemic causes include hematologic disorders, leukemia, atherosclerosis, hypertension, and congestive heart failure.<sup>4,6,8</sup>

In many cases, the precise etiology cannot be clearly identified, and such cases are categorized as primary or idiopathic epistaxis. The incidence of epistaxis demonstrates a bimodal age distribution, commonly occurring in children younger than 10 years and adults older than 50 years. Approximately 9% of children experience recurrent episodes, most commonly originating from the anterior nasal septum. Patients requiring hospitalization are predominantly males older than 50 years, which is

associated with increased healthcare costs. Several factors may explain this pattern. Estrogen is believed to exert a protective effect on the nasal mucosa and vascular structures in premenopausal women. In contrast, men are more frequently involved in outdoor activities and occupations that increase the risk of trauma, as well as having a higher incidence of nasopharyngeal tumors. In older adults, epistaxis is often associated with comorbidities such as hypertension and coronary artery disease, as well as long-term use of anticoagulant medications. Predisposing risk factors include male sex, advanced age, peripheral vascular disease, cardiovascular disease, and a history of previous epistaxis. Younger patients typically present with minor bleeding from the anterior septum caused by nose picking, facial trauma, or foreign bodies in the nasal cavity. Epistaxis in children younger than two years should raise suspicion of systemic disease or possible child abuse.<sup>1,2,9,10</sup>

Secondary epistaxis refers to cases with identifiable underlying causes. Disturbances of the nasal mucosa, coagulation pathways, or platelet function may contribute to bleeding. The management of secondary epistaxis primarily focuses on identifying and addressing the underlying cause, which may be local or systemic.<sup>2,4,6,8</sup>

Nasal trauma frequently results in epistaxis due to mucosal injury, even in the absence of fractures. Fractures of the nasal bones, septum, or paranasal sinuses commonly lead to nasal bleeding. In addition, iatrogenic mucosal or vascular injury during surgical procedures may result in postoperative epistaxis.<sup>1</sup>

Epistaxis during pregnancy occurs in approximately 20.3% of cases. In pregnant women, epistaxis is commonly secondary to pyogenic granuloma, which often develops during the second or third trimester. Pregnancy-related hormonal changes increase nasal vascularity and mucosal fragility, making vessels more susceptible to rupture. The use of decongestants should be avoided due to potential fetal adverse effects, including increased fetal heart rate and associations with congenital abnormalities such as pyloric stenosis. Vascular lesions such as hemangiomas or telangiectasia may also serve as local sources of severe bleeding. Clinicians should carefully balance maternal and fetal risks when considering interventions or anesthesia in pregnant patients.<sup>2,3,11</sup>

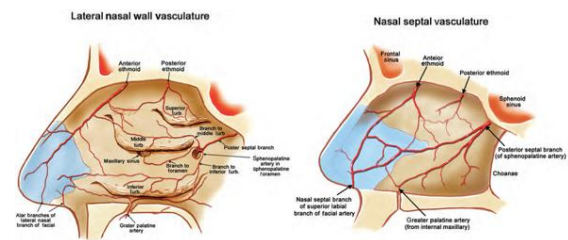
Several studies have demonstrated seasonal variation in epistaxis incidence, with increased frequency during winter months and in dry environments. Dry air leads to desiccation of the nasal mucosa, making it more susceptible to excoriation and bleeding. Additional contributing factors include increased rates of upper respiratory infections, allergic rhinitis, and mucosal changes related to fluctuations in temperature and humidity.<sup>1,2,9,10,12</sup>

Medications are another important risk factor. Drugs such as antiplatelet agents, anticoagulants, intranasal corticosteroids, oral factor Xa inhibitors, warfarin, clopidogrel, and nonsteroidal anti-inflammatory drugs (NSAIDs) have been associated with an increased risk of epistaxis. For example, low-dose aspirin therapy has been reported to increase the incidence of epistaxis compared with placebo (19.1% vs 16.7%). Herbal supplements such as garlic, *Ginkgo biloba*, and ginseng may further enhance anticoagulant effects. Patients taking these medications often have cardiovascular comorbidities, which may worsen hemodynamic responses to bleeding and increase mortality risk. Intranasal corticosteroids have been associated with an approximate 5% risk of epistaxis, although the exact mechanism remains unclear and may involve direct mucosal effects, preservatives, applicator pressure, or improper spray technique. This risk can be reduced by directing the spray toward the lateral nasal wall rather than the septum.<sup>1,2,9,12</sup>

Epistaxis may also be a manifestation of underlying systemic diseases. Chronic hypertension has been associated with the structural changes in nasal vasculature, including arterial muscle degeneration, which may predispose patients to bleeding.<sup>1,2,10,13</sup>

Additionally, coagulation disorders such as hemophilia and von Willebrand disease may present with epistaxis. Vasculopathies, including granulomatosis with polyangiitis and hereditary hemorrhagic telangiectasia, frequently manifest with recurrent nasal bleeding. Hepatobiliary diseases may also cause epistaxis due to secondary coagulopathy resulting from impaired production of vitamin K-dependent clotting factors. Recurrent idiopathic epistaxis should prompt evaluation for tumors of the nasal cavity, paranasal sinuses, or nasopharynx.<sup>1,2</sup>

## Vascular Anatomies



**Figure 1.** Vascularization lateral nasal wall and nasal septal.

The nasal cavity has a rich vascular supply consisting of extensive anastomoses between branches of the internal carotid artery and the external carotid artery. Branches derived from the external carotid artery include the sphenopalatine artery, greater palatine artery, superior labial artery, and lateral nasal artery. The internal carotid artery contributes through the anterior and posterior ethmoidal arteries via the ophthalmic artery.<sup>1,4,9,14,15</sup>

These vascular networks create several areas of anastomosis that predispose the nasal cavity to bleeding. From a functional perspective, the nasal blood supply can be categorized into superior, anterior, and posterior arterial sources.

The anterior ethmoidal artery exits the orbit approximately 24 mm posterior to the anterior lacrimal crest, whereas the posterior ethmoidal artery emerges about 12 mm posterior to this point and 6 mm anterior to the optic nerve. After exiting the orbit, these vessels traverse the ethmoid labyrinth and divide into lateral nasal and septal branches, which supply the superior portions of the nasal cavity.<sup>1,2,15-17</sup>

The facial artery, a branch of the external carotid artery, gives rise to the superior labial artery, which enters the nasal cavity and supplies the anterior septum and lateral nasal wall. Meanwhile, the internal maxillary artery continues medially through the pterygopalatine fossa to form the sphenopalatine artery, the primary arterial supply of the nasal cavity. This artery divides into posterior lateral nasal branches and posterior septal branches, which supply most of the nasal mucosa and anastomose with vessels in the anterior septum.<sup>1,2,15-17</sup>

## Epistaxis Location

Epistaxis is generally classified as anterior or posterior based on the location of the bleeding source.

Anterior epistaxis is far more common and is typically identified during anterior rhinoscopy. More than 90% of cases originate from the Kiesselbach plexus, located on the anterior nasal septum. This plexus is formed by the anastomosis of the anterior ethmoidal artery, septal branches of the superior labial artery, and posterior septal branches of the sphenopalatine artery.<sup>1,2,4,9</sup>

Posterior epistaxis occurs when the bleeding source lies deeper within the nasal cavity and cannot be visualized through anterior rhinoscopy. The most common sites include the superior nasal septum (59.5%), followed by the lateral nasal wall (26.2%) and inferior septum (14.3%). Profuse bleeding frequently originates from the posterior lateral nasal wall due to branches of the sphenopalatine artery. Another potential source is the Woodruff plexus, a venous plexus located in the posterior lateral nasal wall.<sup>1,2,18,19</sup>

### **History, Physical Examination & Laboratory Result**

The initial assessment of a patient presenting with epistaxis should focus on evaluating hemodynamic stability, the severity of bleeding, and the frequency of episodes. Severe bleeding may lead to hypovolemic shock and requires immediate resuscitation while simultaneously addressing the nasal bleeding source. Early interventions, such as topical oxymetazoline and digital compression, may help control active bleeding. Examination of the oropharynx is essential because blood may flow posteriorly during anterior nasal compression.<sup>1,2,5,18</sup>

Patients with active bleeding may be at risk of airway compromise due to blood entering the airway or significant blood loss causing hemodynamic instability. Therefore, a primary survey following airway, breathing, and circulation (ABC) principles should be conducted promptly in emergency settings.<sup>20,21</sup>

Severity assessment may include parameters such as bleeding lasting longer than 30 minutes within 24 hours, a history of hospitalization or blood transfusion due to epistaxis, and more than three recurrent episodes. Additional risk factors include hypertension, cardiopulmonary disease, anemia, coagulation disorders, and evidence of bilateral nasal bleeding or bleeding from the mouth.<sup>20</sup>

Indications for hospitalization including blood loss volume, weakness, the need for posterior nasal packing, and the need for surgical intervention.<sup>12,22</sup>

A thorough medical history should be obtained in stable patients, including details about bleeding duration, estimated blood loss, trauma history, previous episodes, medications, and comorbidities. The use of medications that affect coagulation—including aspirin, NSAIDs, anticoagulants, and herbal supplements—should be specifically investigated. A family history may reveal inherited disorders such as hemophilia or hereditary hemorrhagic telangiectasia.<sup>1,2,9</sup>

Physical examination should include careful inspection of the external nose and anterior rhinoscopy using appropriate lighting and nasal specula to identify bleeding sources, mucosal injury, septal perforation, or dilated vessels. Clots may be removed using suction or cotton pledgets soaked in topical anesthetics and vasoconstrictors to facilitate visualization.<sup>1,2,18</sup>

Posterior nasal examination often requires nasal endoscopy, which has been reported to localize bleeding sources in 80–94% of cases. Endoscopic evaluation is particularly recommended in recurrent or unexplained epistaxis.<sup>1,2,23</sup>

Laboratory investigations may include hemoglobin and hematocrit levels in cases of significant blood loss, as well as coagulation studies in patients receiving anticoagulant therapy or those suspected of having bleeding disorders.<sup>1,2</sup>

### **Management**

The management of epistaxis depends on the identified bleeding source and severity. Treatment should be performed in an adequately equipped clinical environment with monitoring equipment, suction devices, appropriate lighting, and preferably, endoscopic facilities. Personal protective equipment should be used due to the high risk of blood exposure.<sup>1–4,10</sup>

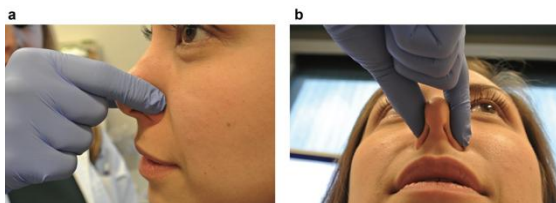
Clinician should inform patient clearly and comprehensively about the benefits of understanding their condition and the available choices. Information provided to patients should include benefits, potential side effects, medications and procedure costs, frequency and duration of treatment, and cultural beliefs or religious considerations related to interventions.<sup>20</sup>

Management strategies generally follow a stepwise approach, beginning with non-invasive methods and progressing to surgical interventions when necessary. Non-surgical treatments include digital compression, topical vasoconstrictors, chemical cauterization, topical hemostatic agents, and nasal packing. Surgical treatments include electrocautery, arterial ligation, and endovascular embolization.

### Medication

The drug used for epistaxis is tranexamic acid. Tranexamic acid is an antifibrinolytic agent that works by competitively inhibiting the binding of plasminogen to fibrin, thereby preventing the formation of plasmin and subsequent fibrinolysis. Tranexamic acid can be administered orally or intravenously. Its antifibrinolytic effect can be applied in many clinical situations requiring reduction of bleeding and prevention of recurrence. Tranexamic acid can reduce nosebleeds after the first treatment, potentially preventing the need for additional interventions such as nasal packing or cauterization and shortening hospital length of stay. It can also be administered every few days after the initial treatment.<sup>9,24</sup>

### Digital Compression



**Figure 2.** Digital compression technique

Non-invasive treatment includes applying pressure to the anterior nasal septum, also known as the Hippocratic method, for 10–15 minutes. Patients are advised to sit upright to reduce venous pressure while leaning slightly forward (sniffing position) to minimize aspiration, swallowing of blood, and airway compromise. Patients should be instructed to pinch the tip of the nose (the lower one-third of the nasal bridge). Patient education is critical because pressure is often incorrectly applied to the nasal bone rather than the anterior septum. Additional useful treatments include topical oxymetazoline applied to the anterior nasal cavity using cotton. The combination of these two procedures can stop bleeding in many patients.<sup>1,2,4,20,25</sup>

Advantages of this technique include being a simple procedure to stop epistaxis, reducing morbidity, protecting the airway, decreasing the need for blood products, and increasing patient satisfaction. Disadvantages of this technique include potentially hindering definitive treatment if needed and causing discomfort for the patient.<sup>20</sup>

### Chemical Cauterization

Refractory anterior bleeding that does not respond to pressure can be treated with chemical cauterization using silver nitrate or trichloroacetic acid applied directly to the bleeding source, which is associated with low morbidity. Extensive use can damage the mucosa without providing additional hemostatic benefit. Chemical cauterization is commonly used for anterior bleeding. The procedure is performed using a cotton swab wetted with a 1:1 mixture of phenylephrine and 4% lidocaine for 10 to 20 minutes. The chemical cotton swab should be held precisely on the bleeding point for 5 to 10 seconds until the mucosa discolors to a grey-white color. The resulting white coagulum is caused by protein denaturation. Cauterization should not exceed 10 seconds or be applied bilaterally on the anterior nasal septum to prevent septal perforation.<sup>1,2,25</sup>

### Topical Hemostatic

Anterior nasal septal bleeding refractory to silver nitrate can be treated with topical hemostatic agents, such as collagen gel matrix, which create a framework for clot formation and promote granulation tissue production. Oxidized cellulose forms an absorbable framework for platelet aggregation and facilitates coagulation, making it useful for both anterior and posterior bleeding.<sup>1</sup>

### Nasal Packing

Bleeding lasting 15 minutes or more may require nasal packing. Nasal packing is indicated when the source of bleeding is not visible on anterior rhinoscopy.<sup>23,26</sup>

Profuse or refractory bleeding that limits adequate visualization requires nasal packing to control the bleeding. Insertion of nasal packing should be performed horizontally, parallel to the nasal floor. Nasal packing reduces bleeding by applying direct pressure to the mucosa and activating the blood clotting cascade. Nasal packing can be

further classified as non-absorbable or absorbable.<sup>1,2,4,20</sup>

Advantages of nasal packing placement include effective and direct bleeding control, reduced morbidity, protection of the airway, decreased need for blood products, and the opportunity to perform additional examination or treatment to control bleeding. Disadvantages of nasal packing placement include failure to control bleeding, delayed treatment, difficulty with additional examination, patient discomfort, mucosal damage during placement or removal, intranasal structural damage (e.g., nasal septal perforation), infection risk, antibiotic exposure, respiratory side effects due to nasal obstruction, dislodgement of the packing, aspiration, eustachian tube dysfunction, obstructive sleep apnea, foreign body reaction, toxic shock syndrome, and the costs of materials and the procedure. Severe side effects may include hypoxia, septicemia, arrhythmia, and myocardial infarction.<sup>4,7,20,23</sup>

#### **Non-absorbable Nasal Packing**

Anterior nasal packing can be performed using gauze coated with Vaseline or antibiotic cream, inflatable catheter balloons, or polyvinyl acetate nasal packing. Nasal tampon placement helps control bleeding by applying direct pressure and promoting coagulation. However, nasal packing is associated with higher morbidity, increased risk, and a greater chance of failure compared with surgical management. Patients with nasal packing are at risk for toxic shock syndrome, a rare condition caused by staphylococcal exotoxin. This syndrome may develop from the first 24 hours up to 5 weeks after sinus surgery and is often accompanied by a foul odor, reflecting rapid bacterial colonization of the nasal packing. Prophylactic antibiotics are recommended to reduce morbidity in these patients. Although surgical management is generally superior, nasal packing can provide temporary hemostatic control if other conservative treatments fail.<sup>1,2,23</sup>

#### **Absorbable Nasal Packing**

Absorbable nasal packing is a more recent development and is increasingly preferred over non-absorbable nasal packing. Materials used include oxidized cellulose, microfibrillar collagen, gelatin derived from cattle or swine, chitosan, and human thrombin solution. The main disadvantage of absorbable nasal packing is that it may not provide sufficient pressure, but its advantages include the

ability to enter the sinonasal labyrinth for direct contact with the bleeding site. This type of nasal packing also dissolves over time, preventing trauma associated with removal.<sup>4,20</sup>

Absorbable nasal packing is recommended for patients on anticoagulant or antiplatelet therapy, or when the nasal mucosa is fragile or affected by coagulopathy. This type of nasal packing is also useful in unfavorable anatomical conditions, such as nasal septal deviation. Absorbable nasal packing is often successful when other treatments have failed. Patient satisfaction and comfort are generally increased with absorbable nasal packing; however, it is more expensive than traditional nasal packing.<sup>2</sup>

#### **Surgical Treatment and Embolization**

Surgical treatment is reserved for patients with bleeding that is refractory to conservative treatment, recurrent or chronic episodes, or life-threatening hemorrhage. The choice of procedure is based on several preoperative factors, the most important being the suspected bleeding site. The purpose of surgical intervention is to isolate and ligate the bleeding artery while minimizing damage to neighboring structures and preserving normal sinonasal function. Surgical treatments include embolization, cauterization, and arterial ligation. Nasal packing may be placed after cauterization or ligation if needed to prevent postoperative bleeding.<sup>2,27</sup>

Conservative treatment may fail to control epistaxis, necessitating more invasive interventions. Embolization has reported success rates of 71–100% (average 88%) in patients, while surgical treatment has success rates of 87–100% (average 90%), with costs varying across institutions.<sup>1</sup>

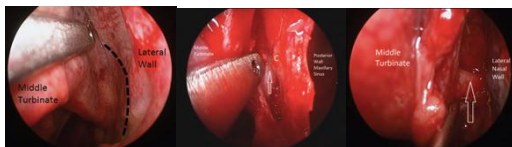
#### **Embolization**

Embolization is an alternative, cost-effective, and impactful method because it can be performed under local anesthesia in patients with multiple comorbidities; however, complications may occur. Embolization can also be used for patients with tumors causing bleeding. It is generally reserved for refractory cases in which surgery has failed to control epistaxis. Siedel et al., Miyandoab et al., and Haye et al. reported embolization success rates of 75%, 88.9%, and 89%, respectively, without significant complications.<sup>1,28,29</sup>

Complications following embolization can be categorized as major or minor. Minor complications are typically self-limited and may include local pain, numbness, swelling, hematoma, skin sloughing, trismus, groin bleeding or pain, maxillary artery spasm, confusion, hypotension, transient ischemic attack, and aspiration pneumonia. Major complications include damage to the intimal layer of the carotid artery, tissue necrosis, facial paralysis, myocardial infarction, blindness, and stroke. These complications occur because embolization is generally limited to vessels of the external carotid artery and cannot directly control branches of the internal carotid artery, such as the anterior and posterior ethmoidal arteries.<sup>1,28,29</sup>

Embolization should be avoided in patients with arteriosclerosis, arterial anastomoses with the internal carotid artery, tortuous or highly curved arteries, allergy to contrast agents, or when the first angiogram demonstrates involvement of the internal carotid artery branches, such as the anterior and posterior ethmoidal arteries.<sup>29</sup>

### Cauterization



**Figure 3.** Sphenopalatine artery identification process

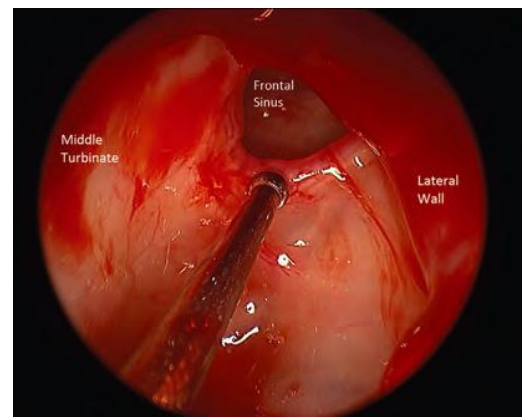
Early surgical treatment for posterior epistaxis includes endoscopic examination under general anesthesia with electrocautery. This approach allows the surgeon to localize the specific bleeding site and selectively cauterize it using bipolar or monopolar suction cautery. Cauterization of the sphenopalatine artery with electrocautery or radiofrequency closes the artery and stops blood flow. Bipolar cautery is preferred over monopolar cautery because the bleeding site is often close to critical nerves or vessels. Bipolar cautery has a lower failure rate compared with silver nitrate (14.5% vs. 35.1%). As with silver nitrate, electrocautery should not be performed bilaterally.<sup>1,2,9,27</sup>

The most common bleeding site after the Kiesselbach plexus is the anterior septum. Suspicion of bleeding from this site should be heightened in patients with intermittent, high-volume epistaxis that is not controlled by nasal packing, as standard packing may not apply sufficient pressure to this area. Suction cautery is generally safe in this location;

however, monopolar cautery near the orbital apex, pterygopalatine fossa, or sphenoid region should be avoided because it may cause neuropraxia due to propagation through surrounding neurovascular structures.<sup>2</sup>

The entire nasal cavity should be examined whenever possible, including the inferior and middle meatus, sphenoidal recess, and nasopharynx, to exclude additional bleeding sites, masses, or lesions.<sup>2</sup>

### Artery Ligation



**Figure 4.** Anterior ethmoidal artery identification on posterior frontal recess.

Artery ligation can be performed if cauterization fails to control bleeding. Artery ligation may involve the internal maxillary artery or the anterior and posterior ethmoidal arteries. Sphenopalatine artery ligation is particularly effective for refractory posterior epistaxis.<sup>1</sup>

Sphenopalatine artery ligation begins with identification of the posterior end of the posterior fontanelle using endoscopy. A mucoperiosteal incision is created along the lateral wall of the middle meatus, extending from the basal lamella of the medial nasal turbinate to the superior end of the inferior nasal turbinate. The subperiosteal flap is elevated posteriorly with a suction elevator (posterolateral mucosal flap) until passing the orbital process of the palatine bone, followed by a vertical incision inferiorly at the posterior end of the medial turbinate, approximately 1 cm anterior to its posterior end. Elevation continues superiorly until the sphenopalatine artery enters the flap at the posterior end of the crista ethmoidalis.

The crista ethmoidalis serves as an important landmark for locating the sphenopalatine artery at the anteromedial aspect of the sphenopalatine

foramen in most cases. If a broader view is required, the crista ethmoidalis can be elevated anteriorly using a rongeur to improve visibility and facilitate identification of the sphenopalatine artery and its branches. Once the sphenopalatine artery is identified, dissection can be performed using an ostium seeker. The artery may be ligated with surgical clips or cauterized with bipolar cautery. Surgical clips can be difficult to place and may shift, so bipolar cautery is the recommended method for vascular control.

Additional arterial branches from the internal maxillary artery or sphenopalatine artery that exit through separate foramina should be identified and controlled during dissection. After completion, the mucoperiosteal flap can be repositioned to its original location.<sup>1,2,27</sup>

An alternative approach involves performing a medial antrostomy to the posterior wall of the sinus, opening the sphenopalatine foramen and pterygopalatine space to access the sphenopalatine artery proximally.<sup>27</sup>

Sphenopalatine artery ligation has a reported success rate of 75–80%. Bilateral ligation carries a risk of nasal septal perforation and medial nasal turbinate necrosis. Some patients may also experience nasal dryness.<sup>2</sup>

Refractory cases requiring palatine artery ligation or bleeding from a superior site may necessitate ethmoidal artery ligation. This procedure is usually performed using an external approach via a medial canthal incision (Lynch procedure). Subperiosteal dissection is continued posteriorly until the ethmoidal artery is identified, clipped, and ligated. The external approach is preferred because it is technically easier and associated with lower risk.<sup>1,2</sup>

### Prevention

Chronic recurrent epistaxis occurs in approximately 15% of the general population. The commonly accepted medical management involves using moisturizing agents or nasal humidification to prevent mucosal dryness. In a study involving the pediatric population, 56% of cases were fully resolved at the next follow-up appointment. Commonly used agents include nasal saline (gel, steam, or irrigation) and essential softening oils. Caution is advised when recommending petroleum-

based softening agents due to the risk of intranasal myospherulosis.<sup>1</sup>

### Post Surgical Epistaxis

Minor epistaxis following endoscopic sinus surgery is an expected risk due to the abundant vascular supply of the sinonasal cavity. Most cases can be effectively managed with conservative treatment. Moustache-style nasal packing may be used to absorb mucus mixed with blood and improve patient comfort. This type of packing typically becomes saturated within a few hours and may require replacement on the first postoperative day. Profuse bleeding warrants endoscopic evaluation. Minor bleeding usually resolves within a few hours, whereas arterial bleeding requires treatment in the operating room through cauterization or ligation. Preventing vascular injury during the initial surgery is crucial to reduce the risk of postoperative epistaxis.<sup>1,26,30</sup>

Large arterial injuries can occur at various locations during endoscopic sinus surgery. If unrecognized and not cauterized intraoperatively, these injuries may result in profuse postoperative bleeding. The posterior septal branch of the sphenopalatine artery runs below the sphenoid sinus ostium and can cause arterial bleeding if damaged during sphenoidectomy. The lateral nasal branch of the sphenopalatine artery may be transected during nasal turbinate resection or posterior extension of a maxillary antrostomy. The anterior ethmoid artery can be injured along the cranial base because it courses posteriorly from the frontal recess. This artery poses a unique risk if transected, as its lateral end can retract into the orbit, potentially causing a retrobulbar hematoma—an ophthalmic emergency requiring immediate lateral canthotomy with cantholysis. The anterior ethmoid artery is particularly vulnerable when located below the cranial base. The risk of arterial injury and minimal bleeding can be further mitigated through preoperative CT scan evaluation.<sup>1,26</sup>

Transsphenoidal pituitary gland surgery can also cause epistaxis, with an incidence of 0.71%. Postoperative epistaxis may lead to serious complications, including asphyxia, hypovolemia, ischemic shock, and death.<sup>30</sup>

### Education

It is important for outpatients to be educated about indications for seeking medical help, as well

as prevention and home management of epistaxis. Non-absorbable nasal packing must be removed within 48–72 hours, whereas patients with absorbable nasal packing should have a hospital visit approximately 1-week post-procedure to assess and remove any residual material. All patients should be monitored for nasal mucosa healing and advised to avoid nose blowing, strenuous activities, heavy lifting, and nasal manipulation for at least 1 week.<sup>4</sup>

The risk of recurrence can be minimized by addressing contributing factors, such as nasal manipulation and forceful nose blowing, and by introducing nasal hygiene measures, including saline irrigation and nasal lubrication with gel. Patients with recurrent epistaxis should sit upright to reduce venous pressure, tilt the body slightly forward (sniffing position), and pinch the tip of the nose (lower one-third) for 10–15 minutes. They should seek medical attention if bleeding is severe or persistent.<sup>4</sup>

## CONCLUSION

Epistaxis is a common otorhinolaryngologic emergency, ranging from mild, self-limiting bleeding to life-threatening hemorrhage. Although most cases can be effectively managed with conservative measures, a comprehensive understanding of its etiology, risk factors, anatomical considerations, and available treatment options is essential for optimal patient care.

Appropriate management involves a stepwise approach, progressing from simple, non-invasive interventions to more advanced surgical or endovascular procedures when necessary. Identification and treatment of underlying causes are essential to prevent recurrence and minimize complications. Additionally, patient education regarding preventive strategies and early management techniques can significantly reduce recurrence rates and improve overall outcomes.

Timely recognition of high-risk cases requiring hospitalization or specialized intervention remains crucial. With appropriate evaluation, evidence-based management, and patient adherence, the morbidity associated with epistaxis can be significantly reduced, thereby improving patient safety and quality of life. *Clinical Practice Points*

Initial management of epistaxis should prioritize airway, breathing, and circulation (ABC) to promptly detect hemodynamic instability and

ensure airway protection when required. For most cases of anterior epistaxis, firm digital nasal compression combined with topical vasoconstrictors remains the recommended first-line treatment. Accurate localization of the bleeding source through anterior rhinoscopy or nasal endoscopy is essential, particularly in recurrent, severe, or unexplained episodes. When conservative measures are unsuccessful, targeted nasal cauterization or packing should be performed, while persistent or posterior bleeding may necessitate surgical or endovascular intervention. In addition, evaluation and management of underlying risk factors—such as hypertension, coagulopathy, and the use of anticoagulant or antiplatelet medications—are crucial to reduce recurrence and guide definitive treatment.

## LIMITATIONS

This narrative review has several limitations. First, it does not follow the systematic methodology of a systematic review or meta-analysis, which may introduce selection bias in the included literature. Second, although recent studies were prioritized, several older landmark references were included to provide essential background on epistaxis. Third, differences in study design, patient populations, and management approaches among the included studies may limit the generalizability of the findings. Therefore, further systematic reviews and large-scale studies are needed to strengthen the evidence regarding optimal evaluation and management strategies for epistaxis.

## ACKNOWLEDGMENT

We would like to thank all the persons involved in this article directly or indirectly for the contribution.

## REFERENCES

1. Wackym PA, Snow JB. Ballenger's Otorhinolaryngology Head and Neck Surgery. 18th ed. People's Medical Publishing House - USA; 2016.
2. Rosen CA, Gray S, Ha P, Limb C, Park S, Richter G. Bailey's Head & Neck Surgery Otolaryngology Sixth Edition. 6th ed. Philadelphia: Wolters Kluwer; 2023.
3. Goswami Y, Gaurkar S. Epistaxis: Pathophysiology and Its Management. 2021;33:17–23.
4. Seikaly H. Epistaxis. *N Engl J Med*. 2021;
5. Modul Rinologi Edisi III. 2022. 1–184 p
6. El-Baz HM, Mohammed KA, Said HS. Risk Factors of Epistaxis in Primary School Children in Dakahlia Governorate, Egypt. 2021;85(October):4035–41.

7. Pandey BR, Singh MM. Evaluation of Epistaxis sites and Its Management in a Tertiary Care Centre. *J KIST Med Coll.* 2022;4(July):11–6.
8. Al-tameemi A. Epistaxis an update management.
9. Kożuchowski M, Prylińska M. Epistaxis etiology and treatment. 2021;11(9):755–60.
10. Ruhela S, Mittal HK, Bist SS, Luthra M, Kumar L, Agarwal VK. Clinico - Etiological Evaluation of Epistaxis. *Indian J Otolaryngol Head Neck Surg* [Internet]. 2023;75(s1):828–35. Available from: <https://doi.org/10.1007/s12070-022-03458-7>
11. Cotter A, Shuttleworth R, Kane AO. Case Report A rare case of life-threatening epistaxis in late pregnancy. 2025;7–9.
12. Hadar A, Shaul C, Ghantous J, Tamovsky Y, Cohen A, Zini A, et al. Risk Factors for Severe Clinical Course in Epistaxis Patients. *Ear, Nose Throat J.* 2023;
13. Lodovica C, Gabriele M, Massimo T, Anna S, Michela P, Abramo R, et al. Epistaxis and Clinic Blood Pressure Values : Is There a Relationship ? 2024;493–500.
14. Drake RL, Vogl AW, Mitchell AWM. *Gray's Anatomy For Students.* Fourth Edi. Philadelphia: Elsevier Inc.; 2020.
15. Alam BS, Jawhari AM, Aljuaid AS, Althomali MA, Almutairi BS, Alobaylan HA, et al. Parents ' knowledge regarding first - aid management of epistaxis in children in Taif , Saudi Arabia. 2023;1–6.
16. Li H, Luo T, Li L, Liu Y, Zhai X, Wang X. Etiology and clinical characteristics of primary epistaxis. *Ann Transl Med.* 2023;11(2).
17. Islam Z, Khanam MA, Karim A, Sagir MG. Management of Epistaxis : A review. *J Patuakhali Med Coll.* 2022;01(01).
18. Lambert EM, Friedman EM. Epistaxis. In: *Management of Bleeding Patients.* 2016. p. 185–90.
19. Ballard L, Fernandez S, Komegay J. Epistaxis : A Clinical Review. 2021;13–8.
20. Tunkel DE, Anne S, Payne SC, Ishman SL, Rosenfeld RM, Abramson PJ, et al. Clinical Practice Guideline: Nosebleed (Epistaxis). *Otolaryngol - Head Neck Surg (United States).* 2020;162(1\_suppl):S1–38.
21. Veetil AK, Lakshmanan J, Shunyu NB, Akthar H, Kuotsu R, Kumari N, et al. Epistaxis : Patterns of Presentation and Management – A Retrospective Study from A Tertiary Institution. *J Otolaryngol Head Neck Surg (North East Branch Assoc Otolaryngol India).* 2025;1(2):6–10.
22. Kallenbach M, Dittberner A, Boeger D, Buentzel J, Kaftan H, Hoffmann K, et al. Hospitalization for epistaxis : a population - based healthcare research study in Thuringia , Germany. *Eur Arch Oto-Rhino-Laryngology* [Internet]. 2020;277(6):1659–66. Available from: <https://doi.org/10.1007/s00405-020-05875-2>
23. Tran QK, Barnett J, Connell FO, Anza BD, Pourmand A. Nasal Packing in the Emergency Department : A Practical Review for Emergency Providers Nasal Packing in the Emergency Department : A Practical Review for Emergency Providers. *Open Access Emerg Med.* 2021;13:527–33
24. Jen- YC, Tou- SL, Tsai Y, Tsai J. Comparative effectiveness of various noninvasive local treatments in patients with epistaxis : A systematic review and network meta- -analysis. 2023;(December 2022):1047–58.
25. Mylonas S, Skoulakis C, Hajjiannou J, Nikolaidis V. Epistaxis Treatment Options : Literature Review. *Indian J Otolaryngol Head Neck Surg* [Internet]. 2023;75(3):2235–44. Available from: <https://doi.org/10.1007/s12070-023-03824-z>
26. Koskinas I, Terzis T, Georgalas C, Chatzikas G, Moireas G. Posterior epistaxis management : review of the literature and proposed guidelines of the hellenic rhinological - facial plastic surgery society. *Eur Arch Oto-Rhino-Laryngology* [Internet]. 2024;281(4):1613–27. Available from: <https://doi.org/10.1007/s00405-023-08310-4>
27. Dispenza F, Lorusso F, Alberto S, Vincenzo D, Dolce A, Immordino A, et al. Management of uncontrolled / recurrent epistaxis by ligation or cauterization of the sphenopalatine artery : a scoping review. 2024;6229–38
28. Miyandoab MR, Onan HB, Piskin FC, Sozutok S, Onan E. Safety And Efficacy Of Transarterial Embolization Therapy In Patients With Uncontrolled Epistaxis : A Single-Center Retrospective Observational Study. 2023;6(1):12–8.
29. Sorour ATAI, Schwager K, Hofmann E. Endovascular intervention in treatment of refractory epistaxis. *SAGE Open Med.* 2023;11:1–8.
30. Liu X, Wang P, Li M, Chen G. after endoscopic endonasal transsphenoidal surgery : a single center experience. 2023;(July). Available from: <https://doi.org/10.3389/fsurg.2023.1203409>