

Laura Wihanto

3-Cryptococcal_meningitis_presenting_

 3-Cryptococcal_meningitis_presenting_

Document Details

Submission ID

trn:oid:::3618:113992047

Submission Date

Sep 24, 2025, 12:43 PM GMT+7

Download Date

Sep 25, 2025, 1:54 PM GMT+7

File Name

3-Cryptococcal_meningitis_presenting_.pdf

File Size

921.0 KB

5 Pages

2,950 Words

15,995 Characters

3% Overall Similarity

The combined total of all matches, including overlapping sources, for each database.





Filtered from the Report

- Bibliography
- Quoted Text




Exclusions

- 41 Excluded Matches

Match Groups

-  **7 Not Cited or Quoted 2%**
Matches with neither in-text citation nor quotation marks
-  **4 Missing Quotations 1%**
Matches that are still very similar to source material
-  **0 Missing Citation 0%**
Matches that have quotation marks, but no in-text citation
-  **0 Cited and Quoted 0%**
Matches with in-text citation present, but no quotation marks

Top Sources

- 0%  Internet sources
- 3%  Publications
- 0%  Submitted works (Student Papers)





Integrity Flags

0 Integrity Flags for Review




Our system's algorithms look deeply at a document for any inconsistencies that would set it apart from a normal submission. If we notice something strange, we flag it for you to review.

A Flag is not necessarily an indicator of a problem. However, we'd recommend you focus your attention there for further review.

Match Groups

-  **7 Not Cited or Quoted 2%**
Matches with neither in-text citation nor quotation marks
-  **4 Missing Quotations 1%**
Matches that are still very similar to source material
-  **0 Missing Citation 0%**
Matches that have quotation marks, but no in-text citation
-  **0 Cited and Quoted 0%**
Matches with in-text citation present, but no quotation marks

Top Sources

- 0%  Internet sources
- 3%  Publications
- 0%  Submitted works (Student Papers)

Top Sources

The sources with the highest number of matches within the submission. Overlapping sources will not be displayed.

- 1** **Publication**
Cecilia Putri Tedyanto, Laura Wihanto, Eric Hartono Tedyanto, Anak Agung Ayu S... **3%**
- 2** **Internet**
www.testmenu.com **<1%**

Ref: Ro J Neurol. 2024;23(1)
DOI: 10.37897/RJN.2024.1.14

Cryptococcal meningitis presenting as simple headache in early adulthood HIV-infected patient: A case report

Cecilia Putri Tedyanto¹, Laura Wihanto¹, Eric Hartono Tedyanto², Anak Agung Ayu Suryapraha Indradewi²,
Ni Made Susilawathi²

¹Department of Microbiology and Parasitology, Faculty of Medicine, Universitas Katolik Widya Mandala Surabaya, Surabaya, Indonesia

²Department of Neurology, Universitas Udayana, Denpasar, Bali, Indonesia

Cecilia Putri Tedyanto **ORCID ID:** 0000-0003-3440-9886

Laura Wihanto **ORCID ID:** 0000-0001-7746-7678

Eric Hartono Tedyanto **ORCID ID:** 0000-0001-9649-5463

Anak Agung Ayu Suryapraha Indradewi **ORCID ID:** 0000-0001-7608-3971

Ni Made Susilawathi **ORCID ID:** 0000-0002-3166-2440

ABSTRACT

Cryptococcal meningitis is a rare disease caused by *Cryptococcus neoformans* or *Cryptococcus gatii* as the fungal pathogen in humans. The disease is highly prevalent in people living with human immunodeficiency virus (HIV) and is the major cause of mortality in an immunocompromised individual. This life-threatening disease does not often occur with specific signs and symptoms. We reported a case of an early adulthood HIV-infected patient with a mild headache and low-grade fever. There was no altered mental status or other significant specific manifestations. Blood examination, chest radiography, and computed tomography scan revealed no significant results. *C. neoformans* were isolated from a culture of the cerebrospinal fluid specimen as the conventional gold standard examination for cryptococcal meningitis. A positive result was confirmed in the India ink staining preparation. The patient was treated with fluconazole monotherapy for the induction and consolidation phase and showed a positive disease progression during observations.

Keywords: cryptococcal meningitis, human immunodeficiency virus, headache, fluconazole

Abbreviations (in alphabetic order):

CDC	– Centers for Disease Control and Prevention	ED	– Emergency Department
CM	– Cryptococcal Meningitis	HIV	– Human Immunodeficiency Virus
CSF	– Cerebrospinal Fluid	KOH	– Potassium, Oxygen, Hydrogen or Potassium Hydroxide
CT-Scan	– Computed Tomography Scan		

INTRODUCTION

Cryptococcus is an encapsulated basidiomycetous yeast with more than 30 species spread in the environment [1]. *Cryptococcus neoformans* and *Cryptococcus gatii* are pathogenic in humans and cause most infec-

tions [2]. The major predisposing factor for cryptococcal infections is the human immunodeficiency virus (HIV) [3,4].

These neurotropism pathogens have cryptococcal-specific factors that allow them to enter across the blood-brain barrier. Some functional interactions with

Corresponding author:
Cecilia Putri Tedyanto
E-mail: cecil@ukwms.ac.id

Article History:
Received: 20 February 2024
Accepted: 30 March 2024

the metalloproteinases and urease enzymes could protect their survival in the brain environment, enhancing the fungal invasion of the central nervous system [5,6]. *Cryptococcal meningitis* (CM) commonly presents with persistent headache, fever, neck stiffness or pain, altered mental status, nausea, vomiting, excessive lethargy and sleepiness, or photophobia [7,8]. Blood or cerebrospinal fluid (CSF) culture is considered the gold standard examination for CM [9-11].

Centers for Disease Control and Prevention (CDC) has reported an estimated 152,000 new CM cases annually, resulting in approximately 112,000 deaths [12]. CM causes around 15% of HIV-related deaths worldwide [13]. One of the significant mortality predictors of HIV-associated CM is the use of fluconazole as monotherapy [14,15].

Although the disease is rare, delays in the treatment due to complex diagnostics in uncommon presentation could worsen the disease. The signs and symptoms are not always specific. It can only be mild or atypical, making it tricky to get a definitive diagnosis. There are also diseases with similar symptoms. The therapy is also challenging since not all health facilities have the standard combination antibiotics.

This case report illustrated how CM could present as a simple headache in an early adulthood HIV-infected patient with no altered or loss of consciousness and other significant symptoms, in which the patient does not even recognize it as a life-threatening neurological disease. This case also reported the outcomes of fluconazole as monotherapy in an immunocompromised individual.

CASE REPORT

A 29-year-old immunocompromised Balinese woman attended the emergency department (ED) with a three-week history of headaches. The pain was throbbing with a mild intensity (Numeric Pain Rating Scale of 3/10), felt all over the head areas but mainly in the frontal area, and came and went away but worsened with activities. The patient also reported delayed nausea and vomiting one night before and a history of mild fever. The fever occurred primarily at night and was well-relieved with antipyretic medication. The patient also reported blurred or double vision, hemiparesis, sei-

TABLE 1. Laboratory findings

Parameter	Result	Interpretation	Reference Range
WBC (x 103/ μ L)	4.54	Normal	4.1-11.0
RBC (x 106/ μ L)	3.38	Low	4.0-5.2
Hb (g/dL)	9.1	Low	12.0-16.0
HCT (%)	29.5	Low	36.0-46.0
MCV (fL)	87.3	Normal	80.0-100.0
MCH (pg)	26.9	Normal	26.0-34.0
PLT (x 103/ μ L)	331	Normal	140-440
BUN (mg/dL)	6.9	Low	7.0-18.7
sCr (mg/dL)	0.72	Normal	0.57-1.11
eGFR	113.16	Normal	\geq 90
ALT (U/L)	16	Normal	< 55
AST (U/L)	25	Normal	< 34
Potassium (mmol/L)	4.09	Normal	3.50-5.10
Sodium (mmol/L)	140	Normal	136-145
Chloride (mmol/L)	110.1	High	94-110
PT (second)	11.2	Normal	10-12.7
INR	0.98	Normal	0.9-1.1
APTT (second)	27.6	Normal	23-34.7
CRP (mg/dL)	8.1	High	< 5
RPG (mg/dL)	76	Normal	70-140
CD4+ (cell/ μ L)	23	Low	404-1612
CD4% (%)	3.76	Low	33-58
CD8+ (cell/ μ L)	387	Normal	220-1129
CD8% (%)	64.61	High	13-39
HBsAg (S/CO)	< 1.0	Non-Reactive	< 1.0 Non-Reactive \geq 1.0 Reactive
Anti HCV (S/CO)	< 1.0	Non-Reactive	< 1.0 Non-Reactive > 1.0 Reactive
Anti-Toxoplasma IgG (IU/mL)	17.4	Reactive	< 1.6 Non-Reactive \geq 3.0 Reactive
VDRL	Negative	-	-
TPHA	Negative	-	-

WBC: White Blood Cell; RBC: Red Blood Cell; Hb: Hemoglobin; HCT: Hematocrit; MCV: Mean Corpuscular Volume; MCH: Mean Corpuscular Hemoglobin; PLT: Platelet; BUN: Blood Urea Nitrogen; sCr: Serum Creatinine; eGFR: Estimated Glomerular Filtration Rate; ALT: Alanine Aminotransferase; AST: Aspartate Aminotransferase; PT: Prothrombin Time; INR: International Normalized Ratio; APTT: Activated Partial Thromboplastin Time; CRP: C-reactive Protein; RPG: Random Plasma Glucose; HBsAg: Hepatitis B Surface Antigen; Anti HCV: Anti Hepatitis C Virus; Anti-Toxoplasma IgG: Anti-Toxoplasma Immunoglobulin G; VDRL: Venereal Disease Research Laboratory; TPHA: Treponema pallidum Hemagglutination

zures, face paralysis, or any aphasia. There were no symptoms or history of injury, cough, coryza, diarrhea, oral ulcers, ear discharge, or tooth cavities. The patient also denied tobacco use, alcohol consumption, drug abuse, multiple sexual partners, or a history of eating undercooked pork. No other past medical disease has been reported. There was a delay in getting to health facilities because the patient thought it was a simple primary headache, as it got better with over-the-counter analgesic drugs.

Physical examination revealed normal tension (110/76 mmHg), heart rate (98 bpm), and respiratory rate (19 bpm), with a low-grade fever (37.6° C) and a normal blood oxygen saturation (99% on room air). Neurological examination revealed compos mentis consciousness (Glasgow Coma Scale of 15) with a positive nuchal rigidity of the meningeal sign. There was an isochoric round pupil (3 mm/3 mm), no defect in cranial nerves, negative lateralization, and negative pathologies reflex.

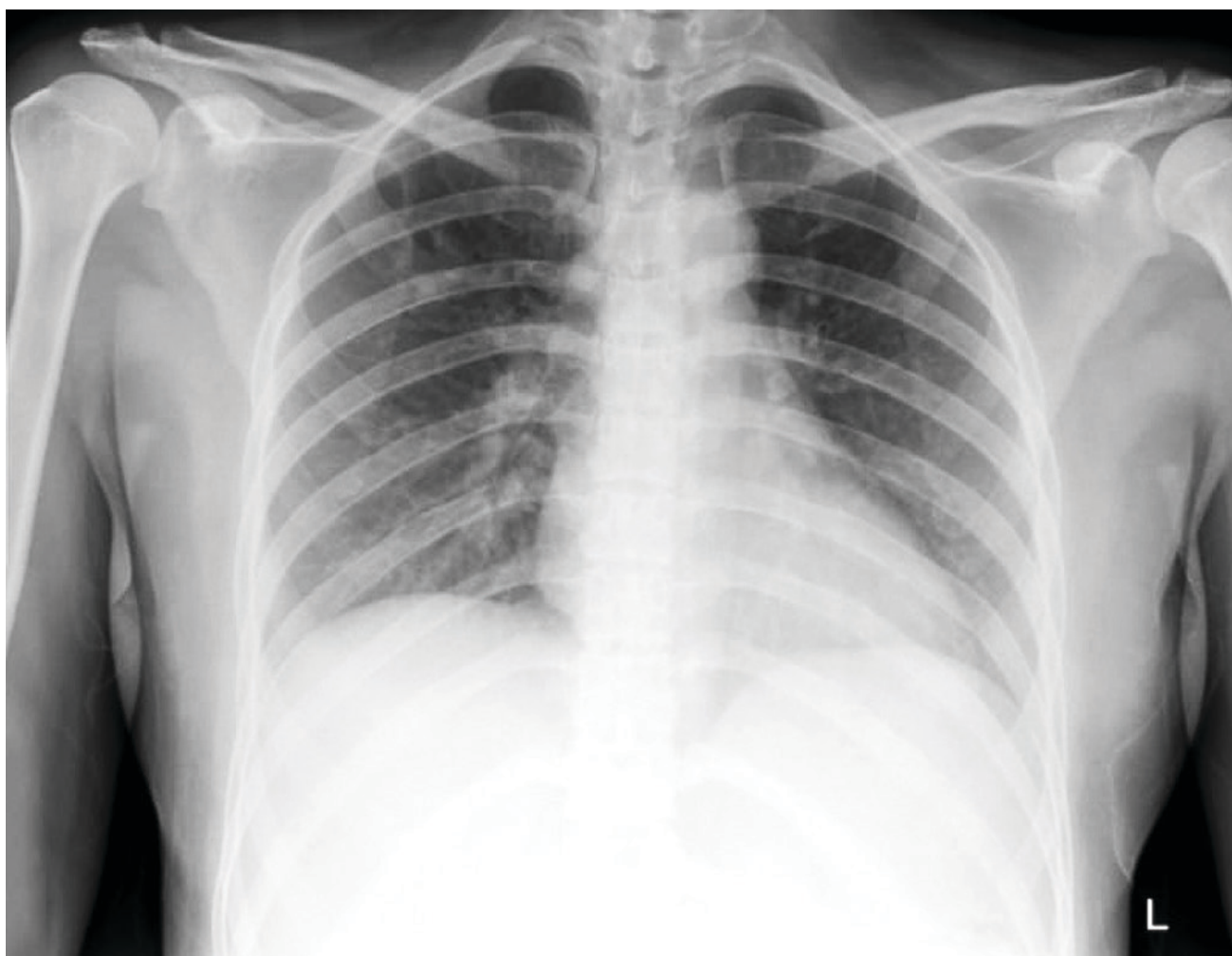


FIGURE 1. Normal anteroposterior chest radiograph

Initial blood examination revealed normocytic normochromic anemia (Hb 9.1 g/dL, MCV 87.3, and MCH 26.9), low RBC ($3.38 \times 10^6/\mu\text{L}$), low hematocrits (29.5%). High CRP (8.1 mg/dL) indicates inflammation. There were no other significant results from the blood examination (Table 1).

Further examination revealed a low absolute CD4 count (23 cell/ μL), low percentage of CD4 (3.76%), normal absolute CD8 count (387 cell/ μL), high percentage of CD8 (64.61%), with a low CD4⁺/CD8⁺ ratio (0.06). A reactive result of anti-toxoplasma IgG (17.4 IU/mL) indicates infection of *Toxoplasma gondii* at some time.

Chest radiograph of anteroposterior view revealed normal soft tissue and bones, a sharp costophrenic angle on both right and left sides, and a normal diaphragm on both sides. The heart size and shape are standard, with a cardiothoracic ratio of 57%. The lung appears to have no significant problem with a normal bronchovascular pattern and no consolidation or nodules (Figure 1). A computed tomography (CT) scan was also performed to rule out the differential diagnosis. The result revealed no mass, infarct, hemorrhagic, cyst, ring-enhancing lesion, or other significant results related to the disease.

Lumbar puncture revealed an opening pressure of 20 mmH₂O with a clear and colorless CSF. The Pandy's reaction reported a positive result, in line with the high amount of total protein (50.5 mg/dL). There was a low CSF glucose level (32%). No other significant result was reported in the microscopic examination of the CSF specimen (Table 2).

The CSF specimen was then further examined for several tests. Direct Gram stain revealed a negative result, potassium hydroxide (KOH) test showed yeast

TABLE 2. Cerebrospinal fluid examination

Parameter	Result	Interpretation	Reference Range
Pandy's Reaction	Positive	-	Negative
Macroscopic			
Color	Clear	-	-
Blood	Negative	-	-
Clots	Negative	-	-
Microscopic			
WBC (cell/mm)	7	High	0-5
Mononuclear (%)	100	-	-
Polymorphonuclear (%)	0	-	-
RBC (cell/mm)	0	Normal	0-5
Total Protein (mg/dL)	50.5	High	< 45
Glucose (%)	32	Low	60-80

WBC: White Blood Cell; RBC: Red Blood Cell

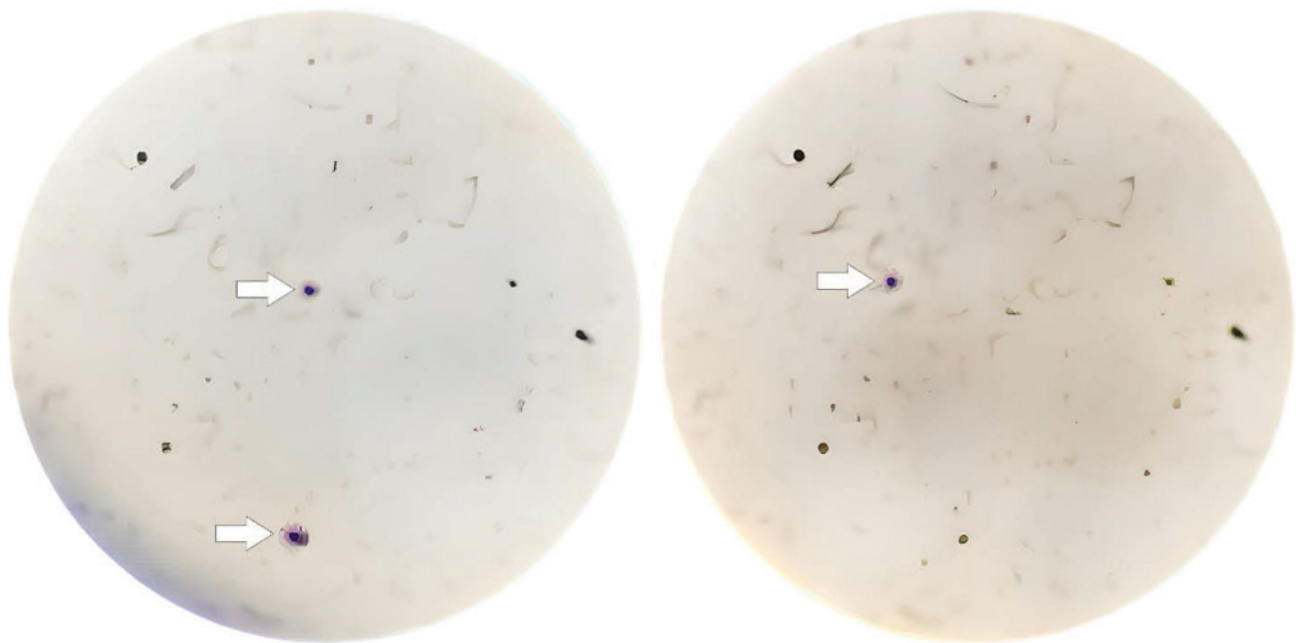


FIGURE 2. Direct India ink staining of cerebrospinal fluid showed yeast forms with thick capsules (white arrows)

cells, and direct India ink staining showed yeast forms with thick capsules (Figure 2). CM was defined, as the CSF culture confirmed the positive isolation of *C. neoformans* from the specimen.

The patient was treated with fluconazole 1200 mg/day for two weeks for the induction phase, then further continued with a dose of 800 mg/day for 8-10 weeks for the consolidation phase. Other supportive drugs include paracetamol, omeprazole, and domperidone as needed.

The patient reported decreased pain intensity and frequency three days after the treatment as time passed. There were no other symptoms, such as fever, nausea, or vomiting. The appetite and sleep quality also gradually improved. A negative meningeal sign was observed in the physical neurological examination one week after the treatment.

The patient was hospitalized for 12 days and then went to the outpatient clinic for further observations. Three days after being discharged from the hospital, the patient reported no complaints. Physical examination revealed normal results. The meningeal signs were negative, and there were no other neurological deficits.

DISCUSSION

CM does not always show a classic presentation. It may present as atypical and improve with non-prescription medicine. Headache or cephalgia should not be treated as a slight symptom, mainly if it occurs in an immunocompromised individual. A cephalgia in a HIV-infected individual that requires special attention if there is persistent cephalgia with any grade of fever, especially if the meningeal sign shows a positive result.

Even in the simplest case, carrying out a careful, detailed, and comprehensive physical examination is necessary. An easy and essential neurological examination, such as meningeal signs, could be ingenious to establish the diagnosis. The diagnosis of CM is quite tricky and challenging, especially in an atypical presentation, with various other possible diagnoses, such as cerebral toxoplasmosis, neurocysticercosis, other bacterial or viral meningitis, intracranial hemorrhage or neoplasm, and many more.

A combination of amphotericin B and flucytosine or fluconazole is considered standard therapy in CM for the induction phase, while the fluconazole and flucytosine combination is recommended as the alternative¹⁶. The limited availability of guideline-based antifungal drugs for CM treatment is another challenge in several health facilities, forcing the use of any available medicine.

The use of fluconazole as a single antifungal medication is reported to be a predictor of increasing mortality rates in HIV-associated CM [14,15]. In contrast, this case reported good results during observation. The patient showed a significant improvement in neurological symptoms and physical examination as the therapy progressed. Other cases using fluconazole as monotherapy for CM also showed promising outcomes [17,18].

There is a need for broad understanding and thinking from a different perspective, not just focusing on the surface of complaints. It is substantial to have awareness from the patient's point of view and knowledge of the possible differential diagnoses from an atypical presentation among physicians to find an earlier diagnosis and more optimal treatment to achieve the best outcomes.

CONCLUSION

Cryptococcal meningitis in immunocompromised patients does not always occur with severe or specific manifestations. It could present as mild and atypical. The disease could also occur in young individuals. Fluconazole monotherapy can be considered an alternative treatment for HIV-associated cryptococcal meningitis because it revealed good improvement in clinical outcomes in this case report, but further research regarding this report is needed.

Patient consent:

Verbal and written informed consents were given by the patient for the publication of this case.

Conflict of interest:

The authors affirm no conflict of interest in this research.

Financial support: none declared

REFERENCES

- Gupta S, Paul K, Kaur S. Diverse species in the genus *Cryptococcus*: Pathogens and their non-pathogenic ancestors. *IUBMB Life*. 2020;72(11):2303-2312. doi: 10.1002/iub.2377.
- Cano EJ, Yetmar ZA, Razonable RR. *Cryptococcus* Species Other Than *Cryptococcus neoformans* and *Cryptococcus gattii*: Are They Clinically Significant? *Open Forum Infect Dis*. 2020 Oct 29;7(12):ofaa527. doi: 10.1093/ofid/ofaa527.
- Rajasingham R, Govender NP, Jordan A, Loyse A, Shroufi A, Denning DW, et al. The global burden of HIV-associated cryptococcal infection in adults in 2020: a modelling analysis. *Lancet Infect Dis*. 2022 Dec;22(12):1748-1755. doi: 10.1016/S1473-3099(22)00499-6.
- Henao-Martínez AF, Gross L, McNair B, McCollister B, DeSanto K, Montoya JG, et al. Risk Factors for Cryptococcal Meningitis: A Single United States Center Experience. *Mycopathologia*. 2016 Dec;181(11-12):807-814. doi: 10.1007/s11046-016-0048-x.
- Tseng HK, Huang TY, Wu AY, Chen HH, Liu CP, Jong A. How *Cryptococcus* interacts with the blood-brain barrier. *Future Microbiol*. 2015;10(10):1669-82. doi: 10.2217/fmb.15.83.
- Vu K, Tham R, Uhrig JP, Thompson GR 3rd, Na Pombejra S, Jamklang M, Bautos JM, Gelli A. Invasion of the central nervous system by *Cryptococcus neoformans* requires a secreted fungal metalloprotease. *mBio*. 2014 Jun 3;5(3):e01101-14. doi: 10.1128/mBio.01101-14.
- Williamson PR, Jarvis JN, Panackal AA, Fisher MC, Molloy SF, Loyse A, Harrison TS. *Cryptococcal meningitis*: epidemiology, immunology, diagnosis and therapy. *Nat Rev Neurol*. 2017 Jan;13(1):13-24. doi: 10.1038/nrneurol.2016.167.
- Centers for Disease Control and Prevention. Symptoms of *C. neoformans* infection. National Center for Emerging and Zoonotic Infectious Diseases (NCEZID), Division of Foodborne, Waterborne, and Environmental Diseases (DFWED). 2020.
- Donnelly JP, Chen SC, Kauffman CA, Steinbach WJ, Baddley JW, Verweij PE, et al. Revision and Update of the Consensus Definitions of Invasive Fungal Disease From the European Organization for Research and Treatment of Cancer and the Mycoses Study Group Education and Research Consortium. *Clin Infect Dis*. 2020 Sep 12;71(6):1367-1376. doi: 10.1093/cid/ciz1008.
- Dantas KC, de Freitas-Xavier RS, Spina Lombardi SCF, Júnior AM, da Silva MV, Criado PR, et al. Comparative analysis of diagnostic methods for the detection of *Cryptococcus neoformans* meningitis. *PLoS Negl Trop Dis*. 2023 Mar 6;17(3):e0011140. doi: 10.1371/journal.pntd.0011140.
- Corrêa-Moreira D, Castro R, da Costa GL, Lima-Neto RG, Oliveira MME. Cerebrospinal fluid: a target of some fungi and an overview. *Mem Inst Oswaldo Cruz*. 2023 Mar 20;118:e220251. doi: 10.1590/0074-02760220251.
- Centers for Disease Control and Prevention. Preventing deaths from cryptococcal meningitis. National Center for Emerging and Zoonotic Infectious Diseases (NCEZID), Division of Foodborne, Waterborne, and Environmental Diseases (DFWED). 2023.
- World Health Organization. Cryptococcal disease: What's new and important. 2018.
- Tenforde MW, Shapiro AE, Rouse B, Jarvis JN, Li T, Eshun-Wilson I, Ford N. Treatment for HIV-associated cryptococcal meningitis. *Cochrane Database Syst Rev*. 2018 Jul 25;7(7):CD005647. doi: 10.1002/14651858.
- Muzazu SGY, Assefa DG, Phiri C, Getinet T, Solomon S, Yismaw G, Manyazewal T. Prevalence of cryptococcal meningitis among people living with human immuno-deficiency virus and predictors of mortality in adults on induction therapy in Africa: A systematic review and meta-analysis. *Front Med (Lausanne)*. 2022 Sep 8;9:989265. doi: 10.3389/fmed.2022.989265.
- World Health Organization. Guidelines for the diagnosis, prevention and management of cryptococcal disease in HIV-Infected adults, adolescents and children: Supplement to the 2016 consolidated guidelines on the use of antiretroviral drugs for treating and preventing HIV infection. Geneva. 2018.
- Correa K, Craver S, Sandhu A. An Uncommon Presentation of Cryptococcal Meningitis in an Immunocompetent Patient: A Case Report. *Clin Pract Cases Emerg Med*. 2021 Nov;5(4):450-454. doi: 10.5811/cpcem.2021.8.53368.
- Hope W, Stone NRH, Johnson A, McEntee L, Farrington N, Santoro-Castelazo A, et al. Fluconazole Monotherapy Is a Suboptimal Option for Initial Treatment of Cryptococcal Meningitis Because of Emergence of Resistance. *mBio*. 2019 Dec 3;10(6):e02575-19. doi: 10.1128/mBio.02575-19.